MOBILE BASED IMAGE ANALYSIS SYSTEM FOR CERVICAL CANCER DETECTION

A Thesis presented to the Department of

Computer Science

African University of Science and Technology

In Partial Fulfilment of the Requirements for the Degree of

Master of Science in Computer Science

Submitted by

Saka Abiola Monsur

Abuja, Nigeria

May 2016

A MOBILE BASED IMAGE ANALYSIS SYSTEM FOR CERVICAL CANCER DETECTION

by

Saka Abiola Monsur

A THESIS APPROVED BY THE COMPUTER SCIENCE DEPARTMENT

RECOMMENDED: _____

Supervisor, Assoc. Prof. Dr Steve A. Adeshina

_____

Co-supervisor, Dr Shola Odusanya

_____

Head, Department of Computer Science

APPROVED: _____

Chief Academic Officer

_____

Date

ABSTRACT

Cervical cancer is the third major killer disease in developed and developing countries. Whereas screening and other preventive measures reduce the mortality rate in developed countries, mortality rates still remain very high in developing countries. This project focuses on the analysis of a digital image of the cervix; captured with a low-level camera, under a contrast agent: the visual inspection with acetic acid (VIA) is known as one of the reference methods to detect cervical cancer. Gaussian and mean filter techniques were used to remove the speckles. A segmentation algorithm was used to isolate the region of interest (ROI) from the image. Additionally a canny edge detection algorithm was used to find edges. Furthermore, quantification and classification of the images were done. An Android application was used to integrate all the above. This allows usage in rural settings. The results obtained were quite satisfactory (Specificity 79% and Sensitivity of 83%).

ACKNOWLEDGEMENTS

I would like to express the deepest appreciation to my project advisor, Assoc. Prof. Dr Steve A. Adeshina, for his thorough supervision and dedication of his time and other resources in making this research work a reality. And also to Dr Omololu Akin-Ojo, who brought up this research idea, Dr Shola Odusanya; who co-supervised this thesis work and finally to Prof. Winston Wole Soboyejo, for his great coordination and support. Indeed, to you all, I am very grateful.

I'm also highly indebted to AUST-PAMI for granting me a scholarship; at a time when nearly all hope had been lost. I promise to be a good ambassador of PAMI.

To all my Professors who taught me during my MSc course work programme, most especially Prof. M.K Traore, Prof. Lehel Csato, Prof. M. Hamada, Prof. Abdulrazaq Abdallah, I say thank you for the great exposure. You contributed immensely to this research work and I remain indebted to you all.

My appreciation goes to all the non-academic staff and departments of this great institution; the Student Affairs office, the ICT office and all the Marlima Cafeteria members of staff.

To all my friends and colleagues who made my stay in AUST a memorable one, you are the best. I wish you all the very best in your future endeavour.

To my beloved parents and siblings, thank you for your support and care in all ramifications.

DEDICATION

This research work is solely dedicated to everyone who has lost his/her battle to the silent killer, CANCER all over the world.

TABLE OF CONTENTS

LIST OF FIGURES

LIST OF TABLES

LIST OF ABBREVIATIONS

AAT	Acetowhite Acid Test
AVD	Android Virtual Devices
AW	Acetowhite
CAD	Computer Assisted Design
CIN	Cervical Intraepithelial Neoplasia
CT	Computed Tomography
DSDM	Dynamic System Development Models
DVM	Dalvic Virtual Machine
FDG-PET	Fluorodeoxyglucose Positron Emission Tomography
FN	False Negative
FP	False Positive
FPF	False Positive Fraction
FPF	False Positive Fraction
GMM	Guassian Mixture Modelling
HIV	Human Immunodeficiency Virus
HPV	Human Papiloma Virus
IDE	Integrated Development Environment
LEEP	Loop electrosurgical excision procedure
MRI	Magnetic Resonance Imaging
NN	Neural Networks
OCT	Optical Coherence Tomography
OHA	Open Handset Alliance
OS	Operating System
PET	Positron Emission Tomography
ROI	Region of Interest
SDK	Software Development Kit
SR	Specular reflection removal
TN	True Negative
TP	True Positive
TPF	True Positive Fraction

TRUS	Transrectal Ultrasonography
VIA	Visual inspection with acetic acid
WHO	World Health Organization
XML	Extensible Markup Language

CHAPTER ONE

INTRODUCTION

1.0 Background of Study

Cervical cancer is one of the curable types of cancers in women if detected early. Most cases of cervical cancer are caused as a result of infection with certain types of Human Papillomavirus (HPV) [4, 6]. Although women who have early exposure to sexual relationships and those with multiple sexual partners are at high risk of contracting HPV and eventually, cervical cancer, it is however possible for a woman to be infected with HPV even if she has had only one sexual partner. In the developed nations, women above the age of 30, who are at high risk of HPV infection, are given HPV vaccines, to reduce the chances of having the disease [4].

Traditionally, optical tests such as VIA, cervicography and colposcopy that employ direct visual examination of the cervix, are becoming popular as a diagnostic tool. Healthcare professionals study the cervix at about one minute after applying the 5% acetic acid to the cervix area. Acetowhite region (AW), which is the suspected region of cervix, and other vascular abnormalities such as mosaicism, punctuation and vasculature may appear [4].

Cervical cancer is second only to breast cancer as the highest cause of cancer-related death of women in the world [1]. In 2012, it was the fourth leading cause of cancer death in women worldwide with an estimate of about 65,700 deaths. Unfortunately, up to 90% of these deaths occurred in the developing nations of the world, especially in sub-Saharan Africa; 60,100 deaths in Africa, 28,600 in Latin America and the Caribbean, and 144,400 in Asia. India, the second most populous country in the world, accounted for 28,600. Latin America and the Caribbean, accounted for 25% (67,500) of cervical cancer deaths [3].

The main reason for this discrepancy is the lack of organized, population-wide, screening programmes and medical personnel to administer and translate various test involved [6].

This thesis work seeks to address the problem of the lack of medical personnel to administer and translate various test by coming up with the automation of cervical cancer detection using digital images of low resolution, deployed on Android mobile devices.

1.1 Problem Statement

More than 80% of the total deaths recorded due to cervical cancer in women have occurred in sub-Saharan Africa. The absence of both the resources for screening to aid early detection, and most importantly, the scarcity of medical personnel to interpret these results is the major contributing factor. Hence, the need to design an Android application, which performs; the analysis and classifies cervix digital image. This will be very useful in the areas with limited or no medical experts.

1.2 Motivation and Purpose

The development in mobile computing in the recent year has made it a great tool in healthcare [5]. These devices are gaining more acceptability due to their portability and reduced price. We are not aware of any existing work done in the deployment of an automated cervical cancer detection tool on mobile platform.

1.3 Research Contribution

A lot of research work has been carried out on digital images for cervical cancer detection. This thesis seeks to contribute to the body of knowledge by using digital images captured with a low-resolution mobile device's camera and also the development of an Android demonstrator as a mobile tool in the automation of cervical cancer detection.

1.4 Research Objective and Scope

This research work aims to design a mobile based digital image analysis system for cervical cancer detection. We seek to achieve the following objectives;

To critical study several algorithms involved in digital image processing and analysis;

To select an appropriate approach suitable for cervical cancer image analysis;

To develop an Android application that serves as a demonstrator for the designed approach; and

To integrate the applications and tools on an Android-based mobile device

1.5 Target Platform

The Android operating system was selected as our platform of choice due to the numerous advantages it offers. It has the largest user base of all the smartphone operating systems. Also,

it is completely open source. Moreover, Android development is relatively easy; most of its syntax and structure are built around the Java programming language and Extensible Markup Language (XML).

Fig 1.0: Smartphone OS market share

1.6 Thesis Overview

Chapter one – introduces the research work, and highlights the research contribution, objectives and scope and the methodology to be employed.

Chapter two – critically looks into the review of literature. Some of the related works are briefly reviewed and basic concepts in digital imaging are discussed.

Chapter three – discusses cervical cancer in detail: the anatomy of the cervix, precancerous and cancerous lesions, causes and preventions etc.

Chapter four – extensively highlights the implemented approach & methods.

Chapter five – presents the result of findings, performance measurement and overview discussions.

Chapter six - concludes the thesis work by summarizing the thesis and suggesting future directions.

1.7 Chapter Summary

This chapter introduces the main thesis work. It highlights the research contribution, objectives and scope, the motivation and purpose, and finally the methodology to be employed.

In the next chapter, we will explore some of the related works that has been done in this realm of research. Some important concepts that relate to this thesis work will also be discussed.

CHAPTER TWO

LITERATURE REVIEW

2.0 Related Works

Much research work has been done in the area of digital image analysis for cervical cancer detection. This ranges from defining several algorithms and methods for the various stages involved in the digital image analysis. Also, great effort has been made in coming up with several Computer Assisted Design (CAD) solutions in this realm of digital imaging for cervical cancer detection.

In 2009, Yeshwanth Srinivasan et al. [7] proposed a unified framework for a fully automated system for the diagnosis of Cervical Intraepithelial Neoplasia (CIN). In their approach, several algorithms that are based on mathematical morphology, and clustering based on Gaussian Mixture Modelling (GMM) in a joint colour and geometric feature space are used to segment the micro regions of the cervix (mosaicism, vasculature and punctuation which made up the Acetowhite region [AW]). Not only are these algorithms of great importance in helping experts to evaluate the inter-capillary distance, which is the most important indicator of severe CIN, but they also help in quantifying precisely the extent of the abnormality.

In their methodology, the whole process of converting the raw cervix image data into a thorough diagnosis of CIN is broken down into six different modules: Segmentation of cervix ROI from the raw cervix image; removal of specular reflection (SR) segmentation of the cervix ROI into acetowhite (AW); columnar epithelium (CE) and squamous epithelium; classification of AW regions into AW, mosaic or punctuation tiles; segmentation of mosaic and punctuation from AW tiles; and assessment of the disease severity.

In their results, the segment obtained using the GMM based clustering correlates with visual perception. Also, the AW region observed, which was detached from the central AW region, is similar to the central AW regions (opalescent region – less intense AW region and which are clinically significant).

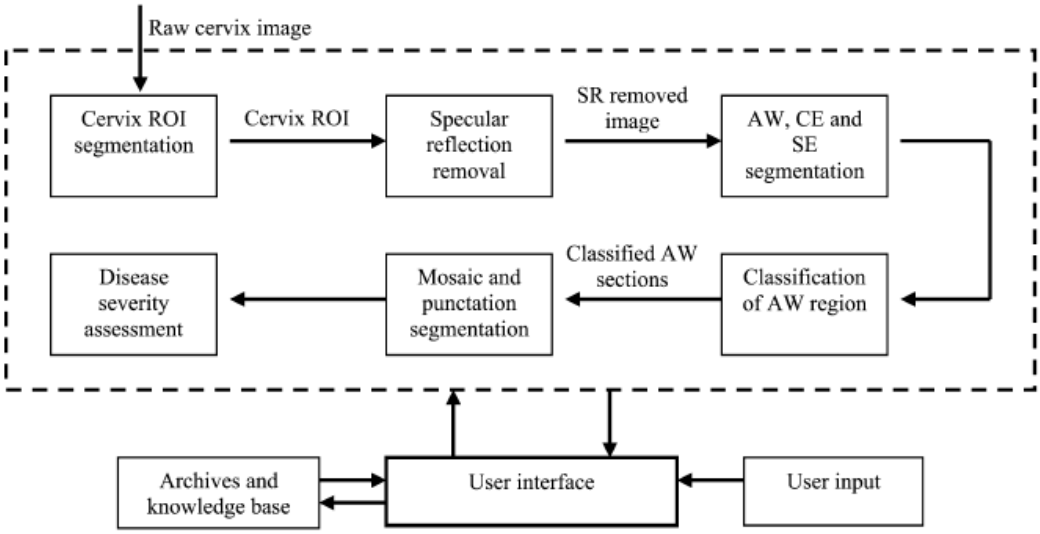

Fig 2.1: Block diagram of the proposed automatic diagnostic tool for CIN [7].

In 2014, Abhishek Das et al. in research work [6], proposed that the elimination of specular reflection and the identification of the ROI as the first step in the automated detection of cervical cancer using digital colposcopy. In their system, the whole scheme was decomposed into four different modules. Specular reflection removal (SR) from raw cervigram; segmentation of cervix ROI; segmentation of cervix ROI into Acetowhite (AW); columnar epithelium (CE) and squamous epithelium(SE); classification of AW regions into AW, mosaic or punctuation tiles. However, they were able to present the first two steps in their work. They took the advantage of advances in vision chip technology to enable high quality image

processing in real time. They also took advantage of the fact that automated analysis algorithms based on modern image processing techniques have the potential to substitute clinical expertise, as a result of which there could be possible reduction in the cost of screening.

The specular reflections in the raw cervigram, which occurred as a as bright spots heavily saturated with white light, resulting from the light illuminating of moisture on the uneven surface of cervix, was removed by finding an interpolating function y that satisfies Laplace's equation in n dimension.

For x € R, | | 0 is a solution of Laplace's equation in n R – {0}. We notice that the function y defined in (1.1) satisfies $\Delta y(x) = 0$ for x 0, but at x = 0, Δy (0) is undefined.

The reason for choosing Laplace's equation (among all possible partial differential equations) is that the solution to Laplace's equation selects the smoothest possible interpolant.

K-means Clustering algorithm was used in segmenting the cervix ROI from the raw image. However, it is possible that the resulting ROI will consist of several disjoint areas in images, and the large one is chosen in this case and others ignored.

A dataset of 200 normal cervigrams and 40 acetowhite cervigrams was used. On visual inspection by domain experts (Gyneco-oncologists) of previous research results, their approach of removing specular reflection performs much better, as their algorithm smoothly interpolates the speckles.

Previous methods have considered only replacing the speckles in the image by blobs. This is a new technique.

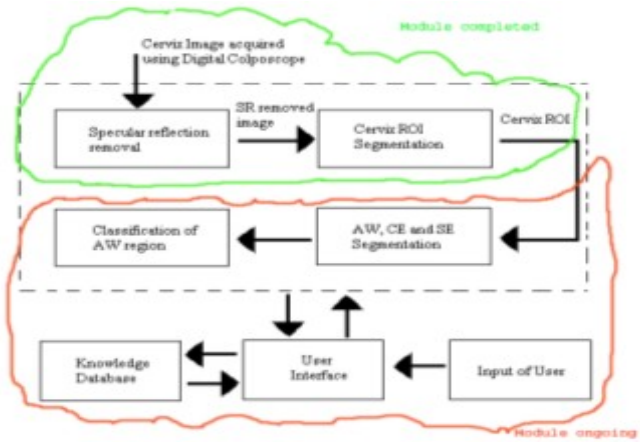

Fig 2.2: Elimination of specular reflection and the identification of the ROI proposed system [6]

Challenges: The system requires well-trained personnel for the evaluation of results.

In the same vein, **in 2014 Suleiman et al.** in their work [2] proposed a novel low-cost methodology in classifying cervical cancer tissues for effective screening in developing countries of the world, having identified the high cost of screening equipment and the limited availability of medical personnel as the factors that are responsible for the high number of deaths resulting from cancer of the cervix in the developing countries, compared to the rest of the worlds.

ImageJ, an image editing tool, was used in enhancing the image; removing the specular reflections in the cervigram raw images, reducing noise and also smoothening the images.

The edge detection technique was used in extracting the feature from the enhanced images. The canny edge detection feature of ImageJ software; which implements the canny edge algorithm, was used to find the intensity of the edges; which could be used in differentiating cancerous tissues from non-cancerous ones.

Images were sourced from the online database. The procedure in taking this picture involves positioning the patient in lithotomy position. Good visualization is obtained with directed light source to the genital area to get a clear view of the cervix. The cervix area is washed with 5% acetic acid with the aid of syringe and after approximately one minute the area is inspected for acetowhite (AW) and the image is captured using a low-resolution camera.

It is from this point that I seek to contribute to the whole body of knowledge by improving on the image processing, primarily by applying an image segmentation algorithm and most importantly, devising an Android demonstrator which performs the algorithm. This is indeed going to be a major landmark in the automation image detection for cervical cancer.

2.1 Digital Images

Digital images can simply be defined as a two-dimensional array of numbers that represents the real, continuous intensity distribution of a spatial signal. This signal is sampled at regular intervals and the intensity is quantized to a definite number of levels. Each element of the array is referred to as a picture element or pixel. The digital image is defined as a spatially distributed intensity signal I (x, y) where I is the intensity of the pixel, and x and y define the position of the pixel along a pair of orthogonal axes usually defined as horizontal and vertical [10]. We shall assume that the image has I rows and J columns and that the digital image has P quantized grey levels with values ranging from 0 to P minus 1 [10, 11].

2.1.1 Image Acquisition

The first stage in any automated digital image analysis system is *image acquisition*. Digital images are captured by different devices [8]. Each medical imaging device captures physical appearance or biological functionalities at the macro or micro levels. These imaging devices include digital microscopes in pathology laboratories, X-rays, Computed Tomography (CT), Magnetic Resonance Imaging (MRI), Mammography, Optical Coherence Tomography (OCT), Colposcopy and Positron Emission Tomography (PET). A medical acquisition device is used to capture the medical images at resolutions sufficient for the human eye or computer-aided analysis.

The image acquisition techniques outlined above are the main categories of medical image modalities. The present research is concerned with the imaging of cervical cancer. Thus, much emphasis will be laid on Colposcopy as an image acquisition technique.

2.1.2 Image Pre-processing

Medical images are often affected by noise due to various sources of interference and some other phenomena that affect the measurement processes of image acquisition systems [10], although some image acquisition techniques are less affected by noise than others [10]. For example, mammographs (X-ray image of the breasts) are less affected by noise compared to some other image acquisition modalities.

Before an image can be analysed for an optimum result, pre-processing is required to reduce the noise and improve the quality of the image in order to determine the ROI. This can be termed as *image enhancement*. Pre-processing includes the filtering process for reducing the noise (salt and pepper), removing of any specular reflections and generally enhancing the

image so that the result is an improvement on the original image. The accuracy of diagnosis depends on the quality of images and the elimination of noise [10].

The result of image pre-processing is an image that shows certain features in a manner that is better in some ways, compared to the original image, thus making it easy to see details that may not be readily seen in the original image [10].

Several algorithms and techniques have been implemented for image pre-processing. Some of these include:

Median Filter for noise removal/reduction;

Mean filter for noise reduction;

Image averaging for noise suppression (involves multiple images);

Edge enhancement algorithms; and

Change enhancement by Image Subtraction (involves multiple images).

However, adequate care must be taking while enhancing images to avoid pitfalls in the pursuit of a better image features. For example, some enhancement techniques may increase noise while improving contrast, while some important parts of the images may also be eliminated while removing noise. Sharp edges especially may be affected in this case. Also, there is no one-single-method-does-it-all for all the images. Each type of image techniques has its unique way enhancement [11].

2.1.3 Image Segmentation

Segmentation is another important step in image processing. It sub-divides an image into its constituent regions or objects. The levels of detailed required are largely dependent on the problem at hand. This stage of image processing determines the success of the whole image analysis process and thus considerable care and caution should be taken to achieve accurate segmentation [11].

Often sample images contain irrelevant information, such as the equipment used, frames, text and other non-image information. For example, in the case of cervical cancer imaging, e.g. colposcopic image or cervigram, these irrelevant details can confuse the automatic

identification of tissue within the cervix [6]. Thus, it is required to cut out the needed area in the image (ROI).

Segmentation can also aid image visualization and compression. Typically, segmentation of an object is achieved either by locating those that form its boundary or by identifying all pixels that belong to the object. The latter is mostly based on the pixel intensity. However, other features such as image texture; that can be associated with each pixel, can also be used for segmentation.

There are different methods used in image segmentation techniques. These include the following: thresholding, region-based segmentation, edge-based segmentation, feature-based clustering and model-based segmentation [14, 15].

Edge-based segmentation

These methods involve detecting the relationship between the neighbouring pixels. It is performed by convolution between gradient operator (e.g. Canny, Sobel, Prewwit and Robert) and image [11, 15].

An edge in an image can be defined by the local pixels' intensity gradient. A gradient is also known as the approximation of the first order derivative of the image function.

Example: for a given image f(x,y), we can calculate the magnitude of the gradient and the direction of the gradient as

Edge detection tends to use high pass filtering that is not suitable for all medical imaging; it depends on the type of image. In histology images, with irregular form and complex histology scenes consisting of the boundaries of regions and noise, it is difficult to distinguish the edge from noise or other geometric features [11].

Region-based methods

Region-based methods operate by looking at the dissimilarity of given criteria.

Aside from using the relationship between the neighbourhood pixels, as seen in edge-based methods, other image features like texture, intensity and colour can be used in mapping out the desired area in an original image. Texture can simply be defined as the correlation between the attributes of intensity that are arranged spatially [12]. Segmentation based on the textual feature of the images has been successfully applied to an array of medical images like cervical, colon and prostate histology images [13].

Threshold techniques

These are the easiest and the most commonly used techniques. Given a single threshold, v, the pixel located at lattice position (x,y), with greyscale value f_{xy} is allocated to category 1 if $f_{xy} <= v$, otherwise, the pixel is allocated to category 2.

In many cases, v is chosen manually, by trying a range of values of v and determining which works best at identifying the object of interest.

The main drawback for this technique is that it is not suitable for complex images [15].

Feature-based clustering

Segmentation is also done through clustering. This technique follows a different approach from those discussed earlier, which is applied directly to the image. Here, the image is first converted into a histogram and then clustering is done on it. Coloured image pixels are clustered for segmentation using an unsupervised technique, fuzzy c. However, if f noise is present in the original image, this may result to image fragmentation.

A K-Means clustering algorithm is a basic clustering algorithm used in image segmentation. It clusters the related image in order to segment the image. It rides on the differences in the intensity and colours in images, thereby making it a purely feature-based algorithm.

Fuzzy clustering technique is used for the segmentation of colour image. This iteratively generates colour clusters using a fuzzy membership function in an image space's colour space. The technique is successful in identifying the colour region [15]. The major drawback of this technique is pixel sorting for labelling

Model-based segmentation

All the above mentioned techniques rely on the local information found within their respective sample image. This method relies on the ability of human vision system recognizing object even if they are not completely represented. However, the available

information that can be gathered from local neighbourhood operators is not sufficient for this task. Rather, some knowledge about the geometrical shape is also required, which can then be compared with the local information. This train of thought leads to model-based segmentation [14].

An inbuilt region smoothness constraint is presented in MRF which is used for the segmentation of colours. MRF is combined with edge detection for identifying the edges accurately [15].

A number of algorithms have been implemented for image segmentations which belongs to one categories or the other. Some of these algorithms are:

K-Mean clustering algorithms; and

Watershed algorithms.

2.1.4 Image Classifications

This is one of the critical stages involved in image analysis. At this stage of image processing, all connected regions are attached to a class. Often region-based features that will sufficiently abstract the object's characteristics are used in the classification process [27].

A classifier can be of three types: supervised (trained), unsupervised (untrained) or those using learning classification [27]. The classification procedures include either numerical (statistical) or non-numerical (syntactic) approaches. Recently, newer approaches of computational intelligence, such as neural networks (NN), evolutionary algorithms and fuzzy logic have been used [27].

2.2 Android Programming

2.2.1 Introduction

Android is a platform and an operating system for mobile devices that is based on a modified version of Linux. Originally, it was developed by a start-up firm, Android, Inc. In 2005, Google purchased Android, after which they took over its development work, including its development team.

In late 2007, a consortium of 47 technology and mobile companies came together around the Android platform to form the Open Handset Alliance (OHA). They alongside Google are involved in the development and improvement of the platform.

Android is completely open source, released under the Apache Open Source License. This gives any developer full unhindered access to the Android source code. Android development is very easy as its Software Development Kit (SDK) is built on the existing programming language and concept. Java is the main construct of instruction while XML is used in its interface rendering. This model makes the platform very popular and earns it wide acceptability.

Android Studio is the official IDE (Integrated Development Environment) for the development of Android projects. It bundles all the needed tools, the Android SDK, the AVD (Android Virtual Devices) and the Android Code Editor.

After the successful development of an Android project, it must be properly signed off before uploading to the Google Play Store, the official market place for Android applications, although there are other stores for Android applications. This is in contrast to Apple which monopolizes its market place.

2.2.2 The Android Software Stack

The Android operating system is made up of consisting of various layers. Each layer has its own characteristics and purpose—but the layers are not always totally separated and often seep into one another.

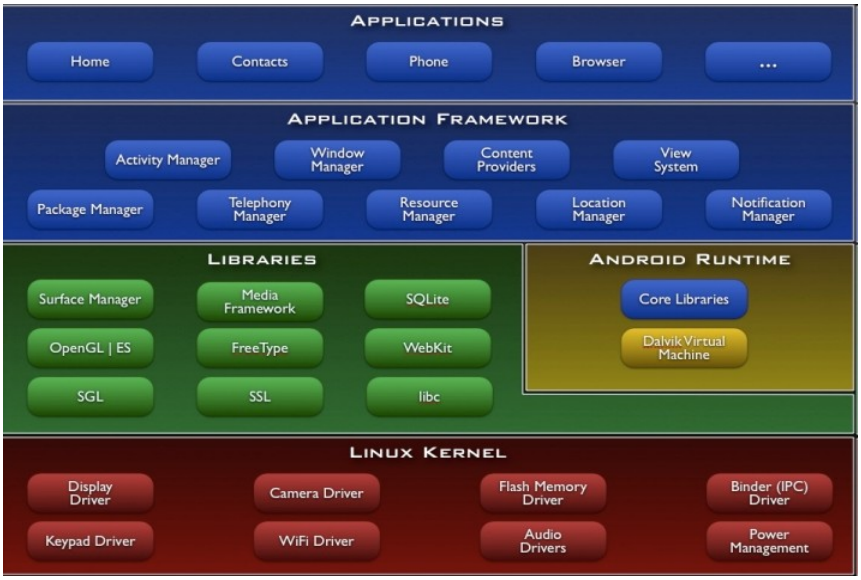

Fig 2.3: The Android Software Stack
Credit: www.developer.android.com/training

Linux Kernel – This provides an abstraction layer between the hardware and the rest of the software stack. It contains all the low-level device drivers for the various hardware components of an Android device.

Libraries – These contain all the code that provides most of the functionality of an Android OS. For example, the "OpenGL | ES" library provides graphics support, while the WebKit library provides functionalities for web browsing.

Android runtime – This provides a set of core libraries that enable developers to write Android applications using the Java programming language provides. It is located on the same layer as the Android Libraries. Dalvik Virtual Machine, an optimized virtual machine for Android is also located on this layer.

Application framework – This is used in accessing the core libraries through the Dalvik Virtual Machine.

Applications – This is the closest layer to the Android users and developers. All the pre-installed applications are located here. This includes contacts, browser, maps, calendar etc. Any third-party application can also be installed on this layer.

2.2.3 Android Building Blocks

The basic element of every Android application development includes the Activity, Services, Intent, BroadcastReceiver and Content Provider.

2.2.3.1 The Activity Class

An Activity corresponds to one user interface screen, which focuses on things that the user can do. It contains the user interface in Android applications, which interact with the users. An application can have zero or more Activities. Often applications have one or more Activities. From the moment an Activity appears on the screen to the moment it is hidden, it goes through a definite number of stages, known as an Activity's life cycle. Understanding the life cycle of an Activity is vital to ensuring that the application works correctly.

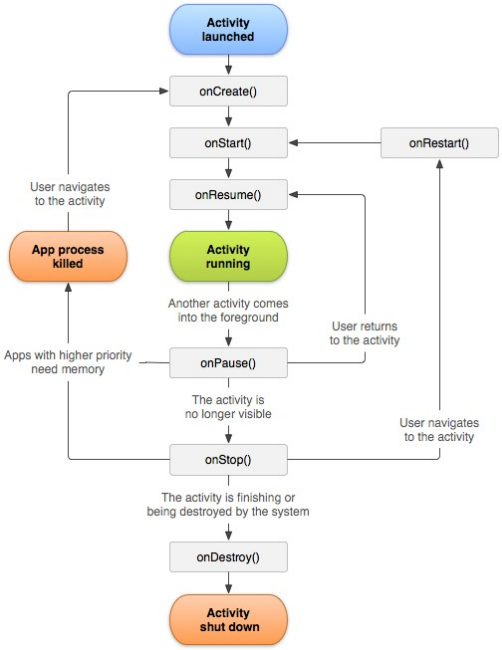

Fig 2.4: Android Activity Lifecycle
Credit: www.developer.android.com/training

2.2.3.2 Services

Android Services are faceless components that run in the background for a long time. Services are among the Android's basic building blocks. Unlike an Activity, a Service does not have a user interface.

Services are used for processes that are meant to run independently of Activities, which may come and go. For example, we can create a Service to periodically check for new contents online and download. This service will always be on and running. Just like an Activity, a Service has a well-defined life cycle.

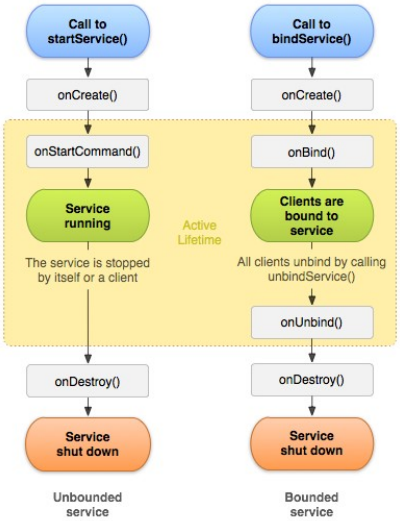

Fig 2.5: Android Services Life Cycles
Credit: www.developer.android.com/training

2.2.3.3 Intent

In Android programming, Intent defines an abstract of an operation to be performed. It provides a mechanism for performing late runtime binding between the components in different applications. Its major use is in the launching of activities, where it can be seen as the glue between Activities. It is essentially a passive data structure holding the description about action to be performed in an abstracted way.

There are two primary forms of Intents.

Explicit Intents – Specify the receiving component and are used in navigating Activities belonging to the same application. Extra data can be passed across to the receiving

Intent by using puExtra() method. They are basically used to navigate between Activities belonging to a same applications

Implicit Intents – do not specify any receiving component; instead, enough information must be provided for the system to determine which of the available components is best to run for that intent.

2.2.3.4 BroadcastReceiver

BroadcastReceiver is executed only when specific event occurs. These could range from the arrival of SMS, network connection, phone call etc. These messages are called Events or Intents. For example, Android can display a message to indicate that internet connection has been made through a specific access point.

There are two classes of broadcasts:

Normal broadcasts are asynchronous in nature. All receivers of the broadcast are executed in an undefined order, often concurrently.

Ordered broadcasts are delivered to a receiver one at a time. After the execution of each of the receivers, it can either propagate a result to the next receiver, or completely abort the broadcast so that it will not be delivered to the other receivers.

More details and documentation is available on the Android official website; www.developer.android.com/training.

2.3 Chapter Summary

In this chapter, we went through the review of literature. Related works and some concept of importance in the research work were discussed. These include; digital images, Android programming etc. In the next chapter, we will look at the concept of cervical cancer extensively. This is important in laying a good foundation in the understanding of our research work.

CHAPTER THREE

CERVICAL CANCER

3.0 Introduction

All forms of cancer start when cells in the body (parts or organs) begin to grow out of control. Cells in nearly any body part can become cancerous, and if not promptly detected and cured, it can spread to other areas of the body [1].

Cancer of the cervix starts in the cells lining the cervix – the lower part of the uterus (womb). This is sometimes called the *uterine cervix*. The fetus grows within the upper part of the woman's uterus. The cervix links the body of the uterus to the vagina, forming the birth canal. The part of the cervix closest to the body of the uterus is called the *endocervix*. The part that is next to the vagina is called the *exocervix (or ectocervix)* [15].

The two main types of cells covering the cervix are *squamous* cells (on the exocervix) and *glandular* cells (on the endocervix). These two cells meet at a place called the *transformation zone.* The exact location of the transformation zone changes as with age and after giving birth.

3.1 Anatomy of Human Cervix

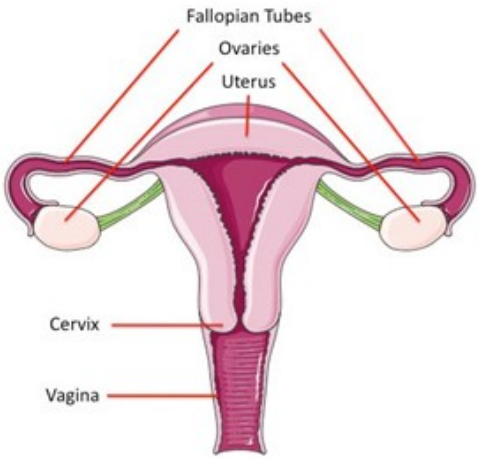

Fig 3.1:Structure of Human Cervix
Credit: repropedia.com/cervix

The uterus, or womb, is a pear-shaped, thick-walled organ made of smooth muscle. The cervix (neck of the womb) makes up the lower third of the uterus and is composed of dense, fibromuscular tissue. The cervix is lined with epithelium, a tissue type consisting of densely packed cells that line all the cavities and free surfaces of the body [1]. The upper part of the cervix (inner cervix or endocervix) is covered with columnar epithelium. The lower part of the cervix (referred to as the ectocervix) lies within the vagina and is covered by squamous epithelium. The area of the junction, where the two types of epithelia meet, is called the transformation zone or squamocolumnar junction [26].

The squamous epithelium has a multi-layered structure that can be grouped into four principal bands of cell types: the basal layer, the intermediate layer, the parabasal layer and the superficial layer. The squamous epithelium rests on the basement membrane, which separates the squamous epithelium from the underlying fibromuscular stroma [26].

The columnar epithelium consists of a singular layer of tall cells that sit directly on the basement membrane. It is thinner than the squamous epithelium.

The cervix varies in shape and size depending on the woman's age, parity and hormonal status. In parous women, it is larger and the external os appears as a wide, gaping and transverse slit. In nulliparous women, the external os resembles a small circular opening in the centre of the cervix [26]. The endocervical canal, which traverses the endocervix, links the uterine cavity with the vagina and finally extends from the internal to the external os, where it opens into the vagina. The area of the cervix varies from one woman to another. This depends on the woman's hormonal status and age. It is widest in women in the reproductive age group, with a measurement of 6–8 mm in width.

3.2 Development of Precancer and Cancer

The transformation zone of the cervix has been identified as being of considerable importance with regard to the occurrence of carcinoma [15].

Almost 90% of cervical cancer cases are squamous cell carcinomas resulting from the metaplastic squamous epithelium of the transformation zone [15]. The remaining 10% are adenocarcinomas developing from the columnar epithelium. Under normal circumstances, cell growth only occurs in the basal layer. However, at the beginning of cancerous transformations, this organization is disturbed with cell division no longer being confined to the basal layer of the epithelium.

3.3 Causes and Symptoms

According to a report from the WHO [3], the primary cause of squamous cervical cancer is persistent or chronic infection with one or more of the so-called high risk or oncogenic types of Human Papillomavirus.

The Human Papillomavirus (HPV) is an extremely common sexually transmitted pathogen [29]. Several types exist, with the most common cancer-causing types being HPV 16 and 18, which are found in 70% of all cervical cancers reported [3]. As viral DNA enters the cervical cell it will, for high-risk HPV types, incorporate itself with the host genome. While HPV is the underlying cause of cervical cancer, most women infected with high-risk HPV do not develop cancer. It is assumed that a number of cofactors exist that can cause an HPV infection to persist and progress to cancer. While these cofactors are still not well understood, the following are considered to probably play a role [3]:

HPV-related cofactors:

Viral type

Simultaneous infection with several oncogenic types

High amount of virus.

Host-related cofactors:

Immune status: people with immunodeficiency (such as that caused by HIV infection) have more persistent HPV infections and more rapid progression to precancer and cancer.

Number of children borne. The risk of cervical cancer increases with the number of children.

Exogenous cofactors:

Tobacco smoking

Co-infection with HIV or other sexually transmitted agents such as herpes simplex virus 2 (HSV-2)

Long-term (>5 years) use of oral contraceptives.

The prognosis for individuals diagnosed with cervical cancer or cervical cancer precursors will be markedly improved if it is detected early [29].

3.4 Treatment and Diagnosis

Cervical lesions in their early stage may be treated with a Loop Electrosurgical Excision Procedure (LEEP), which involves removing the abnormal tissue with a wire loop heated by electric current; cryotherapy (the destruction of cells by extreme cold); cold-coagulation (the destruction of cells by extreme heat); laser ablation (removal of tissue); or conization (the act of removing a cone-shaped piece of tissue containing the abnormal tissue). Invasive cervical cancers are generally treated with surgery or radiation (both external and internal) combined with chemotherapy. Chemotherapy alone is often used to treat the disease at in its advanced stage. However, for women with metastatic, recurrent or persistent cervical cancer, the addition of a drug, Bevacizumab (Avastin®), to standard chemotherapy has been shown to improve overall survival, and has recently been approved in the United States for this use. Cervical cancer survivors may suffer from side effects including sexual dysfunction and impaired fertility; those who are treated with a total hysterectomy will be infertile.

3.5 Colposcopy

Colposcopy is used for the diagnosis and evaluation of CIN and preclinical invasive cancer. This allows magnified visualization of the site where cervical carcinogenesis occurs. The technique enables taking directed biopsy and in describing the extent of lesions on the cervix in screen-positive women, thus avoiding conization. It also helps in managing treatments such as cryotherapy and Loop Electrosurgical Excision Procedure for CIN.

Colposcopy is very limited and not widely practised in many developing countries where the cases of cervical cancer is highly prevalent. Additionally, skills and facilities are lacking for cryotherapy and LEEP, which are the two appropriate and mostly used treatment methods for CIN in low-resource settings.

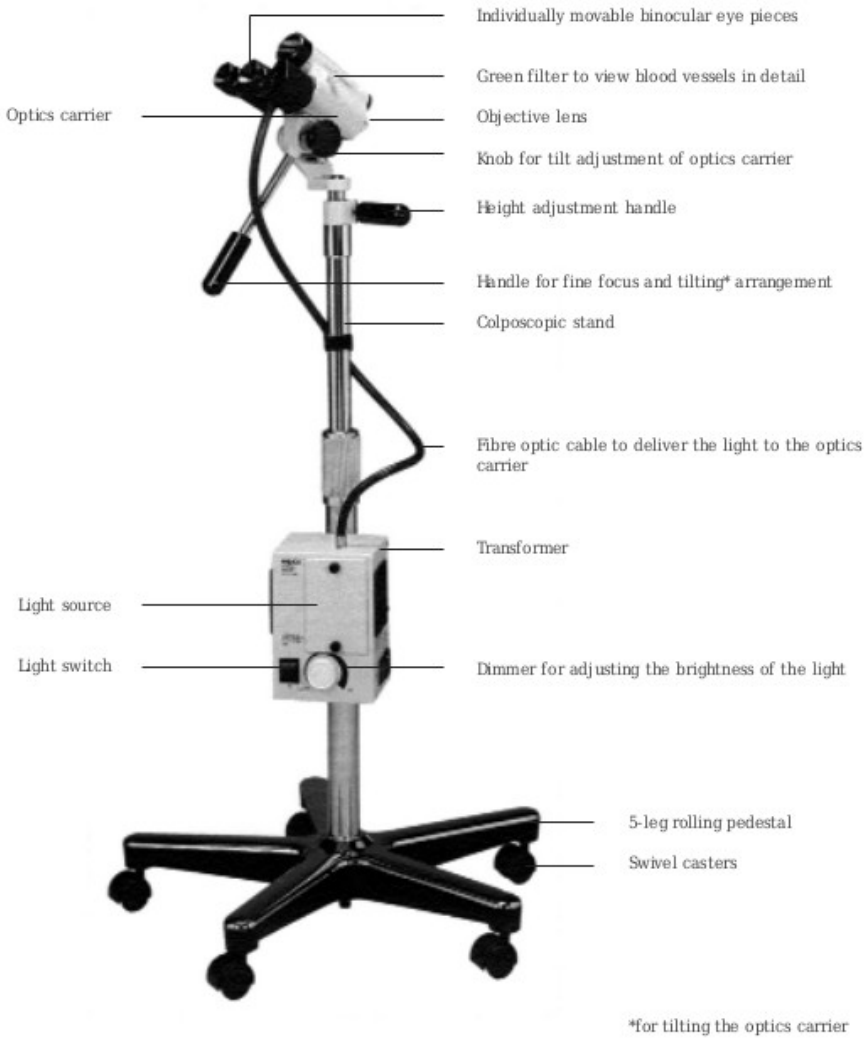
Individually movable binocular eye pieces
Green filter to view blood vessels in detail
Optics carrier
Objective lens
Knob for tilt adjustment of optics carrier
Height adjustment handle
Handle for fine focus and tilting* arrangement
Colposcopic stand
Fibre optic cable to deliver the light to the optics carrier
Transformer
Light source
Light switch
Dimmer for adjusting the brightness of the light
5-leg rolling pedestal
Swivel casters
*for tilting the optics carrier

Fig 3.2: The Colposcope

3.6 Cervical Cancer Imaging

Over the decades, cervical cancer has been staged clinically. Advances in medical imaging could improve the staging of cervical cancer by aiding the detection of lymph node metastases and micrometastasis in distant body organs [17]. Such advancement could lead to an improved treatment selection and in turn, the overall survival rate. Michele Follen et al. in their work [17], reviewed the advances in relevant technology in this real; MRI, CT, lymphangiography, Positron Emission Tomography (PET), ultrasonography, and lymphatic mapping along with their overall impact in the diagnosis, treatment and the survival of cervical cancer patients.

Lymphangiography

This is performed by direct cannulation of the lymphatic ducts with injection of contrast agents that penetrate lymph nodes and cause normal lymph nodes to have an opaque appearance on film. Neoplastic cells are carried through the lymphatic ducts to the known lymph nodes, and lymph nodes that harbor metastatic cells typically do not become opaque after the contrast material has been injected into it. Lymphangiography has been used to diagnose lymph node metastases in patients with cervical cancer since 1961. Lymphangiography reviews report sensitivities ranging from 28% to 83% and specificities ranging from 47% to 100%. In the developing countries, few cervical cancer centres with adequate number of patients use lymphagiography, as the procedures is difficult to perform and its results are difficult to read. Alternatively, hospitals that are unable to perform lymphagiography often resort to using CT or MRI to assess pelvis lymph nodes.

In lymphangiography, false-negative interpretations may occur due to the presence of microscopic metastases and likewise, false-positive interpretations often result from fatty infiltration and inflammatory process.

Ultrasonography

Ultrasound has been defined as a coherent, mechanical vibration of sounds at high frequencies in real time [19]. Piezoelectric materials are used to generate ultrasound. This occurs when there is a change in the thickness of these materials due to the application of voltage across them [17, 19].

Trans-vaginal and trans-abdominal ultrasonography are widely used in gynaecology. In patients with cancer of cervix, ultrasonography is widely useful in quantifying the cancer size and also in identifying enlarged pelvic or para-aortic lymph nodes.

In a similar fashion, transrectal ultrasonography [TRUS] has been used by several investigators to assess the tumour size and paramerial involvement [17].

In recent years, ultrasonography had undergone numerous advances, including colour velocity imaging, the use of time shift rather than Doppler frequency for measuring blood flow velocity and the development of echo-enhancing contrast agents that may provide additional information on tumour vascularity [17].

TRUS has an accuracy of 83% compared with 79% for staging via physical examination. Also, the specificity, sensitivity, and accuracy rates of 92%, 52% and 84%, respectively, for patients that underwent surgical staging for parametrial involvement, compared with 78%, 89% and 87% for patients who were staged with TRUS [17].

CT

CT was developed in the 1970s. Since its development, its array of uses has evolved and expanded in many areas of medicine [17]. The principle behind CT is that a thin collimated beam of X-rays passes through the body to a detector that measures the transmitted intensity [20]. The resulting image is then recomposed into slices of human body, using certain algorithms [17]. Spiral (or helical) CT refers to the CT data recorded as the patient moves through a rotating, continuous, fan-beam exposure.

Advances in CT have made it a rival technique to MRI. Primarily, CT is used in cervical cancer staging to evaluate the size of the cervix and to detect enlarged lymph nodes, obstructions of ureter and lung or liver metastases. Several studies have been conducted which involve comparing the accuracy of helical CT and MRI in the preoperative assessment of parametrial, cancer staging and lymph node involvement. Their positive predictive values are 84.6% vs. 66.7%; their negative predictive values are 90.5% vs. 91.4%; their sensitivity is 64.7% vs. 70.6%; their specificity is 96.6% vs. 89.9%; and their accuracy is 89.5% vs. 85.5% respectively.

MRI

MRI uses magnetic field and pulses of radiofrequency for creating images of organs and internal structure of the body [17, 21]. Mostly, MRI gives different information about structures in the body than can be seen in some other medical imaging like X-rays, Ultrasonography or CT. This results in its likelihood to detect problem that cannot easily be seen using other imaging modalities [21].

Over the decades, MRI has evolved in technical advancement, including improvements in spatial resolution, contrast agents and in particular, speed of imaging, among others [17]. MRI has been shown to be a cost-effective technique and is also considered the most accurate imaging method for preoperative assessment of endometrial carcinoma. This is due to its excellent soft-tissue contrast resolution and multiplanar capabilities [17, 18]. It has also proved to be useful in determining the size of the cervix and in detecting bladder and rectal parametrial invasion. It can also check for the presence and consistency of enlarged lymph nodes, obstruction of the ureter, and lung or liver metastases [17]. T1-weighted and T2-weighted imaging are the common images in MRI [17, 18, 21].

T2-weighted MRI provides excellent detail of normal uterine and cervical anatomy. It also detects the primary tumour and provides information on its extent [17].

At times, endocervical tumours may prove difficult to evaluate clinically, but they are well characterized by MRI. T2-weighted MRI has been reported to have an overall accuracy of 93% in predicting cancer tumour size. In the same vein, approximately 95% negative predictive value of MRI in detecting parametrial invasion has been reported [17, 18]

PET

PET uses a special type of camera and a radioactive chemical (which acts as tracer) to give a picture of organs and internal structure of the body [22]. FDG-PET is the most common type of PET used in cancer imaging. This is because imaging with FDG-PET relies on physiologic processes rather than on the anatomic changes detected by other conventional imaging modalities [17].

FDG-PET has a significant impact in the management of patients with endometrial and cervical cancer (so also MRI) [17, 18]. A few numbers of staging studies have been carried out with cervical cancer patients. FDG-MRI was reported to have a high specificity and sensitivity in the detection of lymph node metastases [17].

Analysis of the post-treatment survival of patients with cervical cancer who were treated at the Mallinck-Rodt Institute of Radiology (St. Louis, MO) indicates the presence of a strong correlation between FDG-PET lymph node findings and patient survival. Tumour volume, which also is correlated with survival, can be directly assessed with FDG-PET.

3.7 Chapter Summary

In this chapter, we examined the concept of cervical cancer in detail: its development, symptoms, causes and treatment. We looked into several medical imaging methods and their respective applications in cervical cancer diagnosis. In the next chapter, we will be looking at the approaches and methods explored in creating our system.

CHAPTER FOUR

APPROACH AND METHODS

4.1 Design Methodology

In any software project, a software development methodology is crucial. In fact it does not only determine the efficiency and the effectiveness of the system, it also helps in planning different activities that are involved in the development processes [23].

The Agile software development methodology was adopted for this project. It can simply be defined as a conceptual framework for undertaking software engineering projects [23]. Many varieties of this method exist with their peculiar features. These includes; Crystal methods, Dynamic System Development Models (DSDM) Extreme programming, Adaptive Software Development, Future Driven Development and Scrum [23, 24].

The desirable features of this development approach made it the best candidate of choice. Some of these include:

1. Stakeholder engagement;
2. High level of transparency;
3. Early and predictable delivery;
4. Predictable cost and schedule;
5. Room for frequent changes; and
6. Focus on the business and the users.

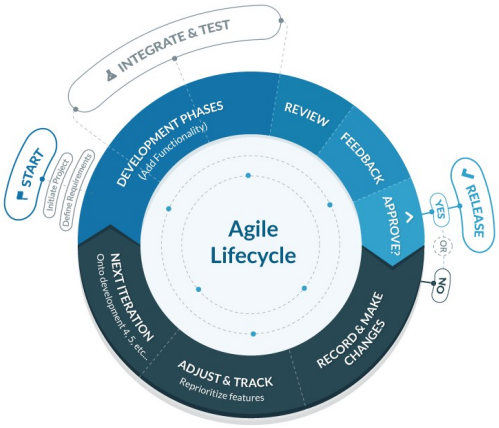

Fig 4.0: Agile Lifecycle
Credit: Captera Project Management Blog; available at blog.captera.com

4.1.1 User Interface Design

The user interface was designed with Extensible Markup Language (XML). Mock up designs were made, in order to guide the actual implementation process. Android Studio is the primary IDE for Android application development. In Android programming, each screen represents an Activity. The interface made use of a few banners and graphics, which were designed using Adobe Fireworks software.

4.1.2 Image Enhancement

Often medical images are degraded by noise due to various sources of interference and some other phenomena that affect the measurement processes during the image acquisition processes [10]. The act of improving on an original image to give a better one is known as image enhancement. This includes removal of noise in the image, smoothing the images and image despeckling. This is necessary for optimum results in the remaining image processing stages. However, adequate care should be taking while enhancing the image so as not to "create another image entirely".

4.1.2.1 Smoothing

Most images do have one form of noise or another. This can vary from salt and pepper noise, multiplicative noise, among others. Noise is anything in the image that we are not interested in. The resulted image from smoothing process gives a more accurate image.

4.1.2.2 Image Specular Removal

During the process of image acquisition, through a digital camera, light falls on the uneven surface of the cervix, and specular reflection appears in the resulting image. This appearance

is characterized with a bright spot, heavily saturated with a white light. This bright spot may hinder the image analysis process.

A despeckle algorithm was implemented in Android programming. The algorithm looks for these heavy bright spots in the image and convolutes it with the RGB values of the pixels surrounding it.

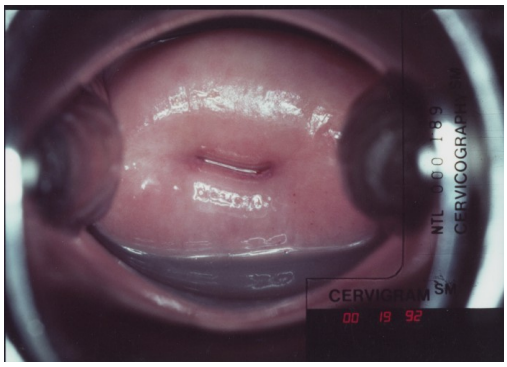

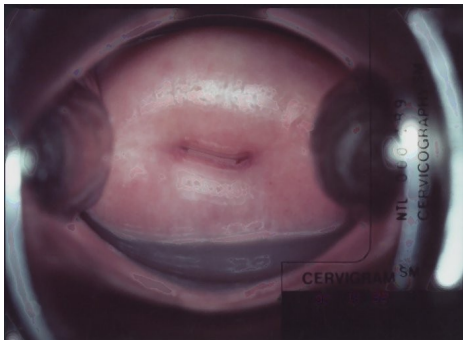

(a) (b)

Fig 4.1: a) Original image b) After specular removal.

4.1.3 Conversion to greyscale

For better manipulation and efficient use of computing resources, it is better to operate with a greyscale image, rather than a coloured image. The image is converted into greyscale using various Java classes like Pain, ColorMatrix, Canvas, Bitmap etc.

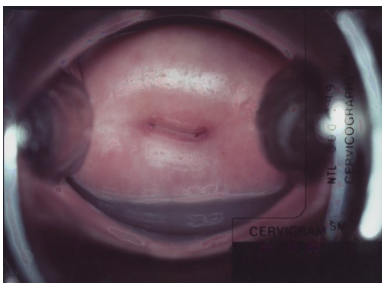

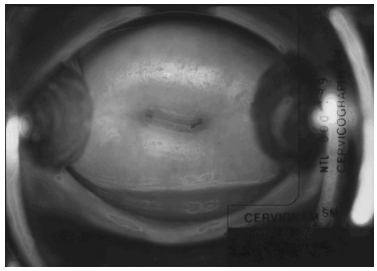

Fig 4.2: (a) Image without Specular removal (b) Its greyscale equivalent

4.1.4 Image Segmentation

Most medical images are accompanied with irrelevant information which can affect the analysis process. It is therefore pertinent to separate these ROI images. Many techniques and algorithms have been discussed in the literature. These techniques include Region-based, Thresholding, Edge-based techniques, feature and model-based segmentation [14, 15], while several algorithms have also been implemented: K-Means Clustering algorithm, Watershed

algorithm among others. Thresholding technique was adopted for the purpose of this research. This is because it is the easiest and the most commonly used techniques. Given a single threshold, t , the pixel located at lattice position (i,j), with greyscale value f_{ij} is allocated to category 1 if

$$f_{ij} <= t$$

Otherwise, the pixel is allocated to category 2. Category 1 represents the ROI while category 2 is the irrelevant part of the image or the image background. T was chosen by manually trying out several values of the algorithm. Threshold value of 95 happens to perform optimally at identifying the object of interest. Each pixel in the other category is converted to black.

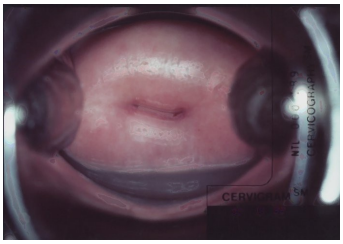

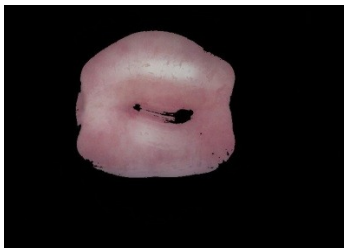

(a) (b)

Fig 4.3 a) original image b) ROI segmentation

4.1.5 Edge detection

After successful image segmentation, we look out for the presence of edges in the ROI. This is known as edge detection. Edge detection is a technique defining a set of mathematical methods which aim at identifying points of discontinuity in a digital image. In digital image processing, several features can be chosen in classifying the image. This includes intensity of the image, and of course, the edges in images. This approach is one of the best for cervical cancer imaging. Several edge detection algorithms have been implemented, for example canny edge, Sobel, Prewitt, and Kirsch [9]. These can be largely categorized under Laplasian techniques and Gaussian techniques. Amidst all the aforementioned edge detection methods, canny edge has been rated as the best [9]. Hence, it was adopted for this research. Its algorithm was implemented in Android programming. The procedure involved in the canny edge detector is as follows:

1. Smoothen the image to reduce noise, using Gaussian filtering;

2. Compute the intensity gradient;

3. Non-maximum suppression; and

4. Tracing edges with hysteresis.

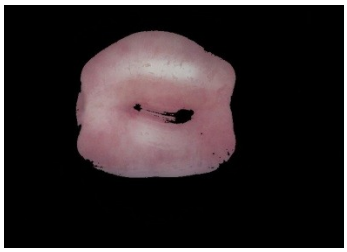

(a)

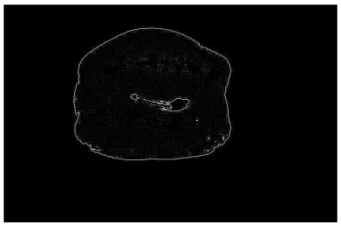

(b)

Fig 4.4: a. ROI image b. Edges in the image

4.1.6 Image Classification

There is a great relationship between the frequency of edges in the image and the possibility of cervical cancer occurrence [2]. The mean grey value of the resulting edges in the image is calculated. From these values, mean and standard deviations are also calculated. A threshold value is chosen whereby any image that resulted in a mean below or equal to the threshold value is adjudged to be free of cancer, while the one just a little above the threshold value indicates a great possibility of the presence of cervical cancer at its early stage; CIN1 . Lastly, any image with a mean value of far above the threshold value has high tendencies of the presence of chronic cancer, CIN2 or CIN3.

4.1 Conceptual Diagram

The figure below shows all the components of this research work with a schematic diagram.

The image is either pre-loaded from the memory of the device running the application or the image is captured directly by the device camera. The first step after the image capture is image enhancement. Principally, this involves the removal of speckles in the image. The resulting image is converted to greyscale for easy computation. Then the next stage is for the

ROI to be segmented from the image. After successful segmentation, the edges in image are identified. Finally, the image is classified, and the result is displayed on the mobile device.

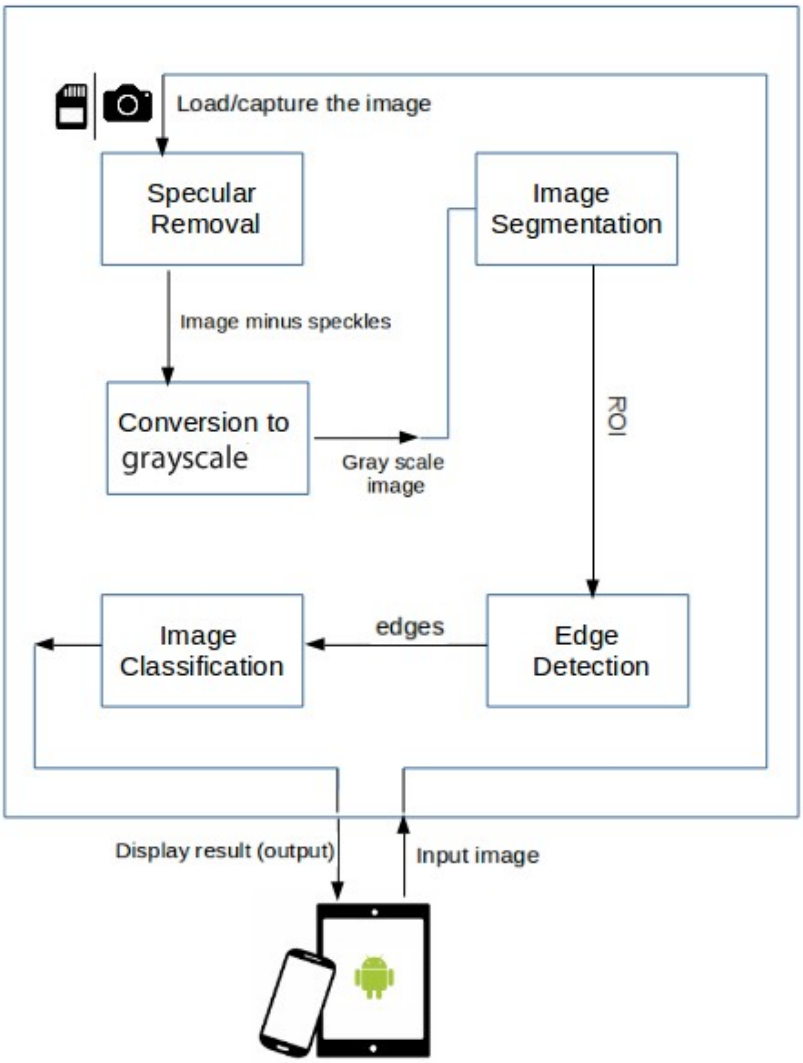

Fig 4.5: The proposed Conceptual Design

4.2 System Design

Activity and Class diagrams will be used to show the different component and functionalities that our system is composed of.

4.2.1 Activity Diagram

The activity diagram for our proposed system is as shown in fig 4.6. Activity diagrams, which are related to program flow plans (flowcharts), are used to illustrate Activities. In the external view, we use activity diagrams for the description of those business processes that describe

the functionality of the business system. The following illustrate the series of Activities and processes in our system.

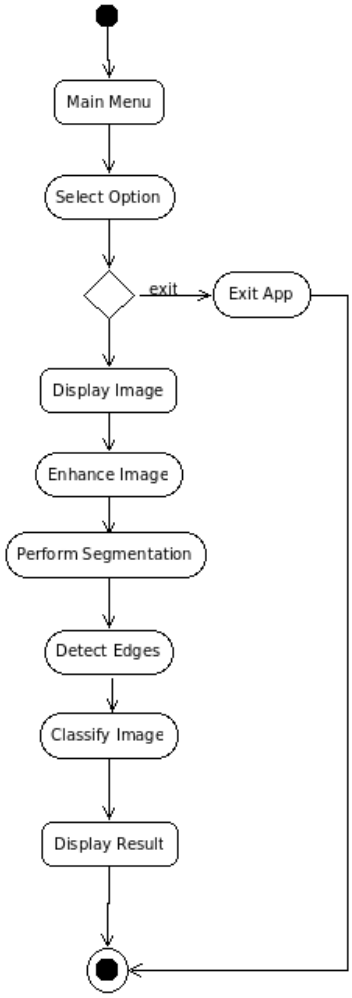

Fig 4.6: Our System's Activity Diagram

4.2.2 Class diagram

The following shows the relationship between different classes implemented in this research work, with their respective parameters and methods.

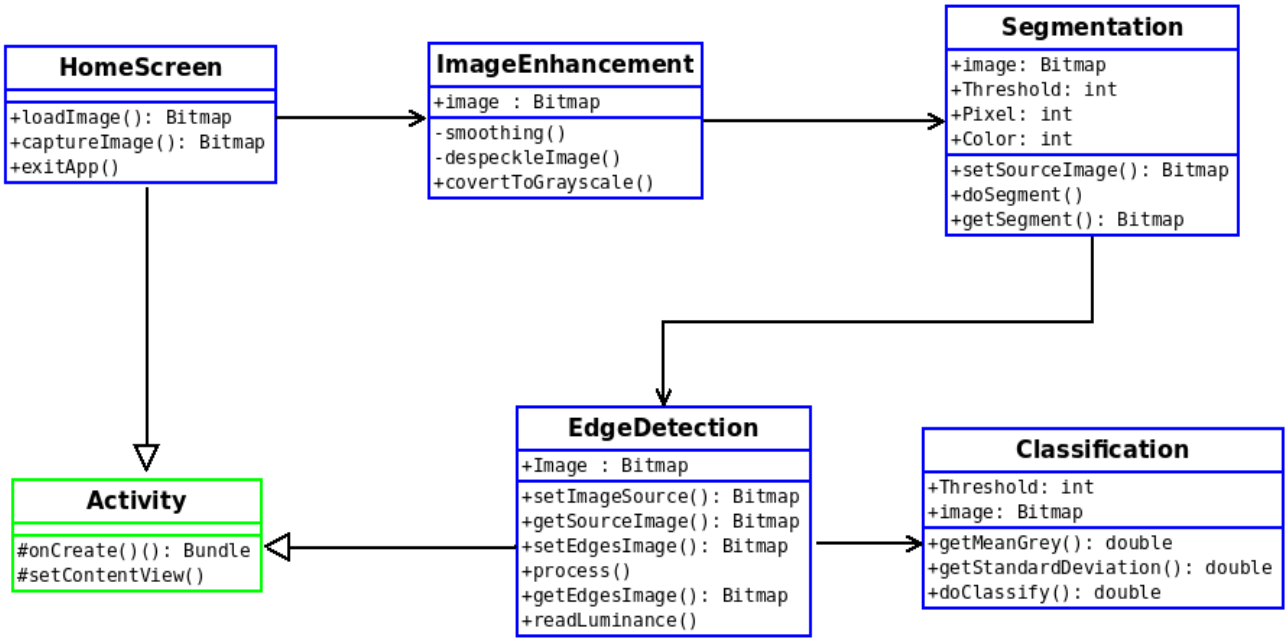

Fig 4.7: Our System's Class Diagram

4.3 Chapter Summary

In this chapter, several methodologies and approach were investigated. Several algorithms and methods were implemented as well. In the next chapter, we will discuss the result of our implementation. Also, the performance of our system will be measured.

CHAPTER FIVE

RESULT AND DISCUSSIONS

5.1 Data Set

The images were sourced from an online image database; Geneva Foundation for Medical Education and Research (GFMER) [24]. A total of 24 classified images was used in this research work. The classification was made by VIA by experts in the field of oncology. Out of these images, six images show no reaction with acetic acid, 15 indicate probably an early stage of cervical cancer (CIN I and few CIN II) while the last three indicate a chronic stage of the disease (CIN III and infiltrating cancer).

5.3 Performance and Measurement

In the last few decades, a large increase in the number of diagnostic tests in the field of medicine had been witness, and thus the need for personalized medicine will bring about rapid increase in this in the nearest future [25]. As a result of this, there is great need for careful evaluation of any potential testing procedure, so as to limit their potential danger to humans.

There are two basic diagnostic evaluations of these tests:

Sensitivity

Specificity.

Some key terms will be used in defining the above terms:

True Positive: Detecting no disease/condition when it is actually present

True Negative: Detecting no disease when it is not present

False Positive: Detecting a disease/condition when it is not present

False Negative: detecting no disease when it is actually present.

5.3.1 Sensitivity

Sensitivity of any diagnostic test can be defined as its ability to correctly detect a condition when such is truly present. The proportion of positive diagnoses among the people who are correctly identified to have a disease is called the sensitivity measurement and it is denoted by;

If no abnormality is detected, the sensitivity becomes low or ranges from 0 to 1, where a sensitivity of 1 means the abnormality is detected with 100 percent accuracy.

The True Positive Fraction (TPF) is equal to sensitivity.

5.3.2 Specificity

Specificity is measured based on the proportion of the population who do not have the disease/condition. It is the ability of a test not to detect a condition when such is not truly present.

If specificity is equal to 1, all normal conditions are detected. The goal of this measurement is ideally to increase the sensitivity and specificity to the highest level (or 100%). Perfect sensitivity is obtained from the system that always identifies and decides the existence of abnormality whereas perfect specificity is achieved from the system that always identifies and decides non-abnormalities. The False Positive Fraction (FPF) is a fraction defined as True Negative divided by the number of abnormalities.

5.4 Results

The following table summarizes the results of our system on the 24 images from our data settings.

Table 5.1: Results table

S/N	Doctor's Classification(VIA)	Cancer Mobile		
		Mean	Classification	Comment
1	Normal cervix, negative AAT	4.0	No cancer	True Negative
2	Normal cervix, negative AAT	4.0	No cancer	True Negative
3	Normal cervix, negative AAT	5.0	No cancer	True Negative
4	Severe postmenopausal atrophy of the squamous epithelium, negative AAT	6.0	No cancer	True Negative
5	Cervical polyp, negative AAT	5.0	No cancer	True Negative
6	Normal cervix, negative AAT. Ectopy is present with metaplastic epithelium growing medially at 12 o'clock (containing crypt openings)	10.0	Infiltrating Cancer	False Positive
7	Marked ectopy, negative AAT	6.0	No cancer	True Negative
8	Nabothian cyst at 5 o'clock. Atypical acetowhite lesion at 11 o'clock extending up into the canal	2.0	No cancer	False Positive
9	Atypical lesion anteriorly, positive AAT - repeat screening in 6 months' time	4.0	No cancer	False Positive
10	Acetowhite metaplastic epithelium anterior and posterior. Atypical lesion at 12 o'clock (at the periphery)	7.0	Traces of Cancer (CINI)	True Positive
11	Condylomata acuminata at 10 o'clock	5.0	No cancer	True Negative
12	Negative with acetowhite metaplasia. Crypt openings are present within metaplastic epithelium. At 1 o'clock Nabothian cyst is present (yellow). False-negative AAT	7.0	Traces of Cancer	True Positive
13	Normal with acetowhite metaplasia in the transformation zone. False positive AAT	5.0	No cancer	True Negative
14	Condylomata acuminata at 6 o'clock, acetowhite metaplasia anterior	2.0	No cancer	True Negative
15	Atypical acetowhite lesion extending up into the canal	1.0	No cancer	True Negative
16	Positive AAT. Probably normal, but a biopsy is desired in order to rule out cancer	1.0	No cancer	True Negative
17	Positive AAT. Probably normal, but abnormal blood vessels indicate biopsy	8.0	Traces of cancer	True Positive
18	Low grade SIL (CIN I) at 12 o'clock with acetowhite metaplastic epithelium posterior	7.0	Traces of Cancer	True Positive
19	Positive AAT, low grade SIL (condylomata acuminata)	7.0	Traces of cancer	True Positive

20	Positive AAT, high grade SIL anterior (CIN II)	3.0	No cancer	False Negative
21	Positive AAT, high grade SIL (CIN III) at 5 o'clock. Acetowhite metaplastic epithelium anterior	0.0	No cancer	False Negative
22	Leukoplakia before application of Acetic acid; probably high grade SIL (CIN III)	8.0	Traces of cancer	True Positive
23	Infiltrating cancer	10.0	Infiltrating cancer	True Positive
24	Infiltrating cancer	12.0	Infiltrating cancer	True Positive

The above table can be summarized using a bar chart as shown:

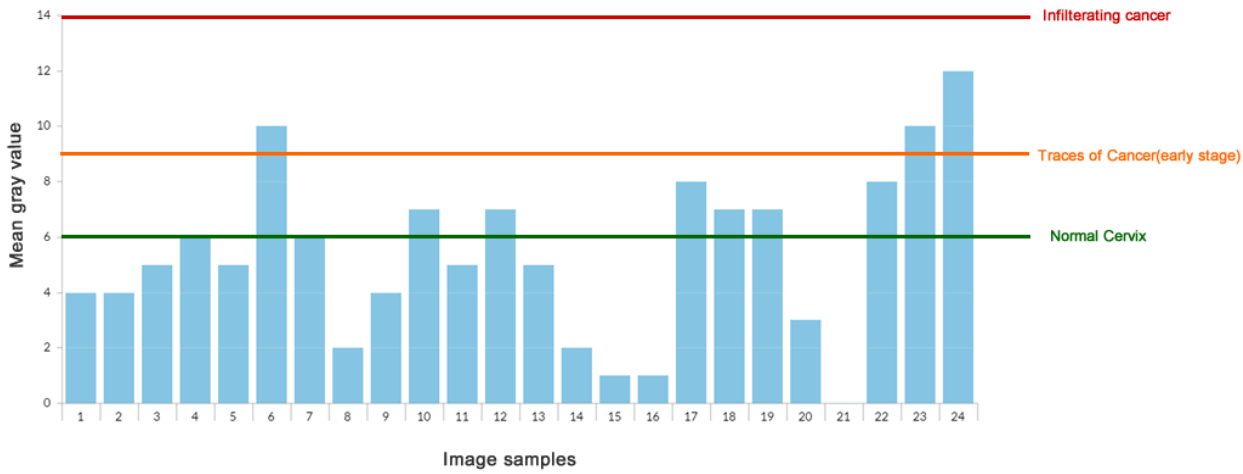

Fig. 5.1: A bar chart summarising the result

5.4 Discussion

All the objectives set in this research work have been satisfactorily met. This novel approach of packing all the activities of assessment into a mobile device will go a long way in reducing the number of deaths arising from cases of cervical cancer. Since it will aid early detection of the condition, which is the main key to survival. In addition, this simple tool can be used in rural settings where there are no medical experts.

There are three conditions of cervical cancer cases:

Firstly, if the analysis resulted in a low mean grey value, it means there are fewer edges in the image; therefore, there is no case of cervical cancer.

Secondly, if the mean grey value is slightly above the threshold value, this could indicate a trace of cervical cancer in its early stage. However, there is a possibility of this being a False Positive, resulting from some conditions in the sample image such as camera reflection, glare from acid pool or darkness from blood on the wall of cervix. In this case, a confirmatory test like biopsy can be suggested.

Finally, a high mean grey value relative to the threshold value, as a result of multiple edges from; the proliferated, bulging or mushroom-like growth on the surface of the sample image indicates a high grade cervical cancer (CIN III or Infiltrating Cancer) and thus, requires a very urgent medical attention.

Performance measurement

The table below shows the performance of our system in term of the specificity and the sensitivity.

Table 5.2: Showing the measurement of our system's performance

No of TP	8	No of TN	11
No of FN	2	No of FP	3
Sensitivity	83%	Specificity	79%

5.5 Chapter Summary

This chapter presents and discusses the result from our implementation. Specificity and sensitivity have been used as the indices for measuring the performance of our system. In the next chapter, we will summarize the whole research work and recommend some future directions.

CHAPTER SIX

SUMMARY, CONCLUSION AND FUTURE WORK

6.1 Summary

In this research work, we have been able to bring image analysis computation to a mobile platform. This is indeed a novel realm in cervical cancer imaging. The outcome of this is a portable tool that runs on Android platform. In our approach, we have used edges as a feature in classifying cervical cancer images. These images were taken with a low-resolution camera after the application of 5% acetic acid.

The irrelevant part of the image was segmented by using thresholding technique. The canny edge detection algorithm was implemented for the edge detection.

In addition to a robust algorithm being implemented, a simple and effective user interface was provided for both image acquisition and result display.

6.2 Conclusion

A thorough review of literature was done to ascertain the level of work done in this research field.

We have been able to devise a portable Android mobile application for the analysis of cervical cancer images. This system is limited to Android devices and some hybrid versions of Blackberry devices, thus leaving out the iOS devices user. The Android mobile platform was given preference due to its large user base.

All our set objectives in the introductory chapter of this research work have also been satisfactorily met.

6.3 Future Work

This study is limited by the number of data sample used (images). Therefore further research work is recommended with more image samples. This will not only assist in adequate testing and evaluation, it will aid using more sophisticated model that requires more images in both analysis and classification stages.

More efficient knowledge based approach especially in the image classification stage should be considered. This can be an online-based system which can be used as a decision support

system in case of any ambiguity in the result offered by our system, which may be due to limited resources present on the host mobile devices, among other reasons.

REFERENCES

[1] American Cancer Society. Cancer Facts & Figures 2015. Atlanta: American Cancer Society; 2015. Available at /www.cancer.org/acs/groups/content/@editorial/.../acspc-044552.pdf

[2] Suleiman Mustafa, Steve Adeshina, Mohammed Dauda and Wole Soboyejo "Classification of cervical cancer tissues using a novel low cost methodology for effective screening in rural settings" IEEE, 2014

[3] World Health Organization Global Health Observatory Data Repository, Mortality and Global Health Estimates 2012

[4] Abhishek Das, Avijit Kar, Debasis Bhattacharyya; "Detection of abnormal regions of precancerous lesions in Digitised Uterine Cervix images"; IEEE, ISBN 978-1-4799-3174-3/14, 2014

[5] Usman Arshad, Cecilia Mascolo and Marcus Mellor; "Exploting mobile computing in health-care", IWSAWC, 2014

[6] Abhishek Das, Avijit Kar, Debasis Bhattacharyya, "Elimination of Specular reflection and identification of ROI: The first step in automated detection of cervical cancer using digital colposcopy" IEEE, ISBN 978-1-61284-896-9/11, 2014

[7] Yeshwanth Srinivasan,Enrique Corona, Brian Nutter,Sunanda Mitra, Sonal Bhattacharya, " A Unified Model-Based Image Analysis Framework for Automated Detection of Precancerous Lesions in Digitized Uterine Cervix Images" IEEE JOURNAL OF SELECTED TOPICS IN SIGNAL PROCESSING, VOL. 3, NO. 1, FEBRUARY 2009

[8] A. F. Zuluaga, M. Follen, I. Boiko, A. Malpica, and R. Richards-Kortum, "Optical coherence tomography: A pilot study of a new imaging technique for noninvasive examination of cervical tissue," American journal of obstetrics and gynecology, vol. 193, pp. 83-88, 2005

[9] Raman Maini & Dr. Himanshu Aggarwal, "Study and comparism of various image edge detection techniques", International Journals of Image Processing, Vol 1,

[10] Isaac N Bankman, "Handbook of medical imaging processing and analysis", Academic press, ISBN 0-12-077790-8, 2000

[11] Gonzalez, R. C., and Woods, R. E., Digital Image Processing 3rd Edition Addison-Wesley, Reading, MA, 1992.

[12] M.Clark, A. Bovik, and W. Geisler, "Texture segmentation using a class of narrow band filters," IEEE, 1987.

[13] K. Hammouda, Jernigan, "Texture Segmentation using Gabor Filter."

[14] Sun Microsystems, Programming in Java Advanced Imaging, Release 1.0.1, November 1999

[15] Android development training; available at

[16] John W. Sellors, R Sankaranarayanan, "Colposcopy and Treatment of Cervical Intraepithelial Neoplasia: Beginner's guide", IARC Press, 2013, ISBN 92 832 0412 3.

[17] Michele Follen, Charles F. Levenback, "Imaging in Cervical Cancer", American Cancer Society, 2003.

[18] Patel, Shilpa et al. "Imaging of Endometrial and Cervical Cancer."*Insights into Imaging* 1.5-6 (2010): 309–328. *PMC*. Web. 8 May 2016.

[19] RadioInfo.org, available at , retrieved on 8 May 2016

[20] Computed Tomography, Scientific/Technological fact sheet, available at , retrieved on 8 May 2016

[21] Magnetic Resonance Image, available at retrieved on 8 May 2016.

[22] Positron Emission Tomography, available at , retrieved on 8 May 2016.

[23] Ian Sommerville, "Software Engineering",9th Edition, Pearson Education Press, 2011, ISBN 978-0-13-703515-1

[24] Cervical Cancer Images, available at;

[25] Women's Health: Cervical Cancer, Available at , Retrieved on 20th May 2016

[26] Anatomy of the cervix and the Transformation Zone: available at; , Retrieved on 20th May 2016

[27] Thomas M. Deserno, "Fundamental of Biomedical Image Processing", Springer Press, 2011, ISBN 978-3-642-15815-5

APPENDIX

Screen shots



Splashscreen activity

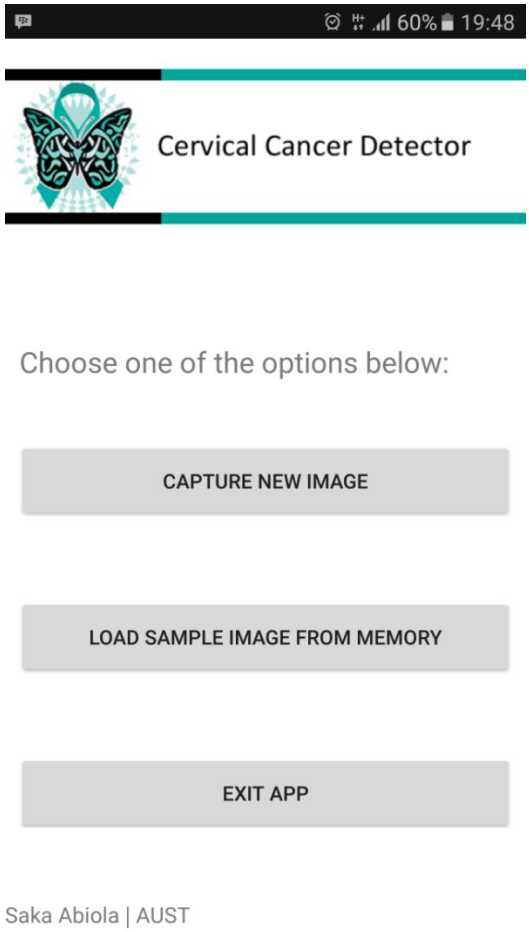

Homescreen Activity

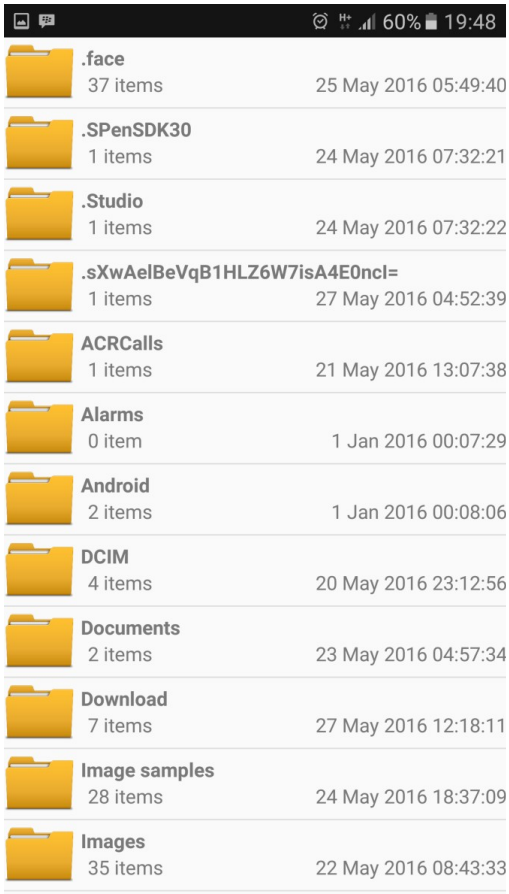

File Chooser activity

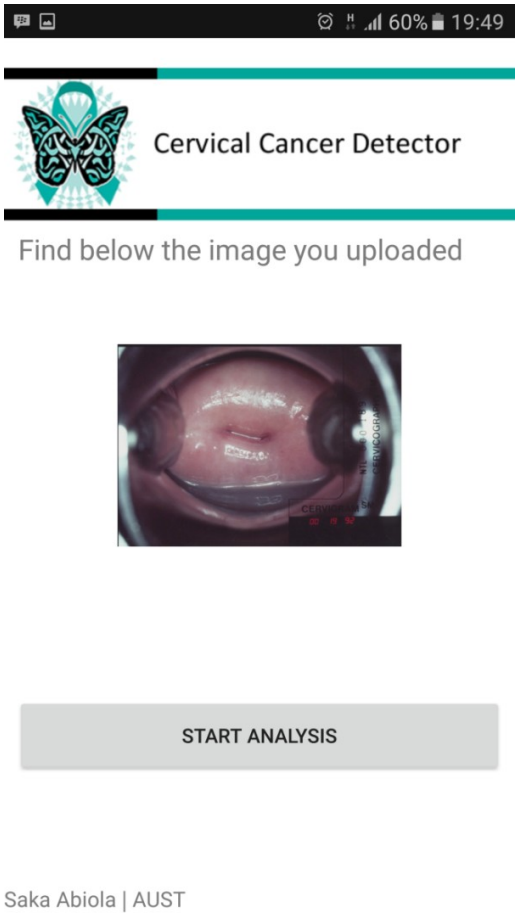

Image display activity

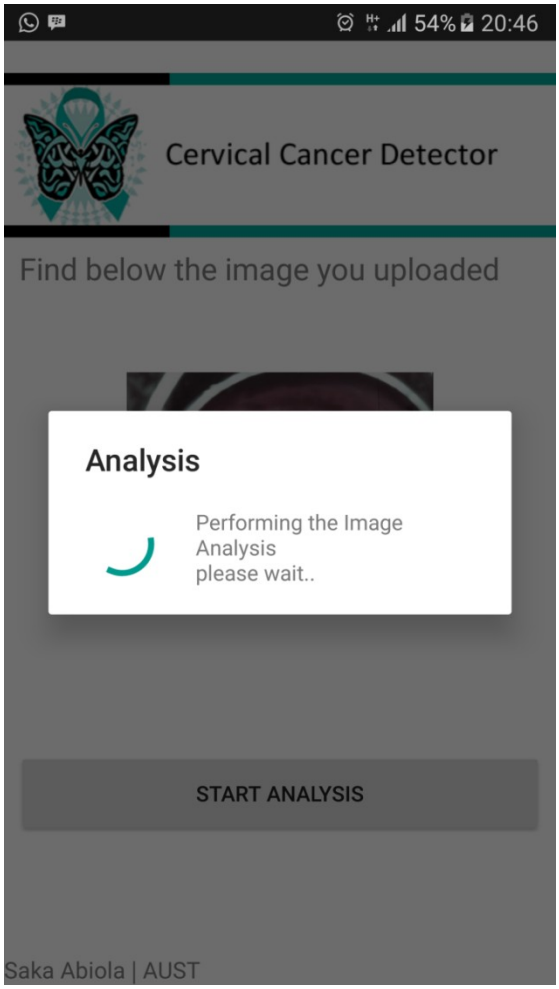

Analysis in progress

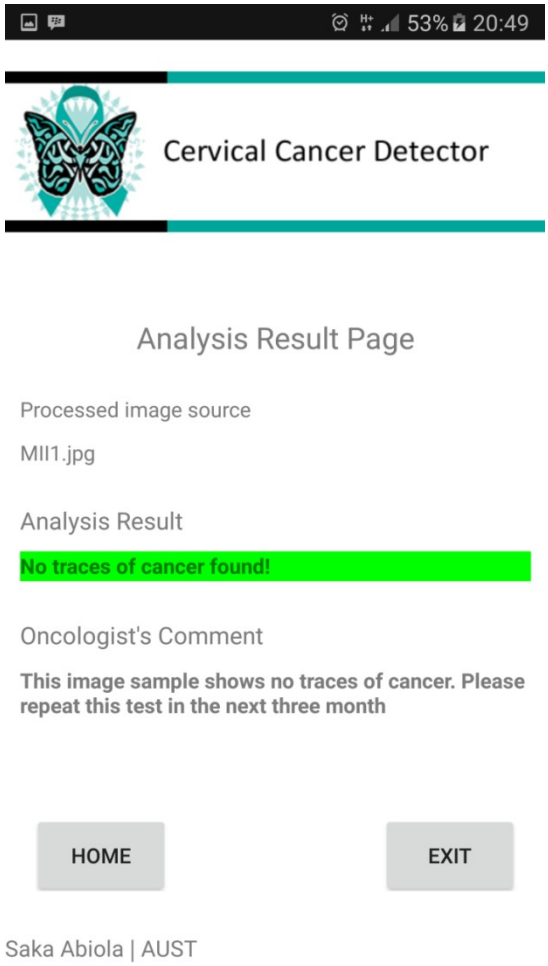

Result page – No cancer found

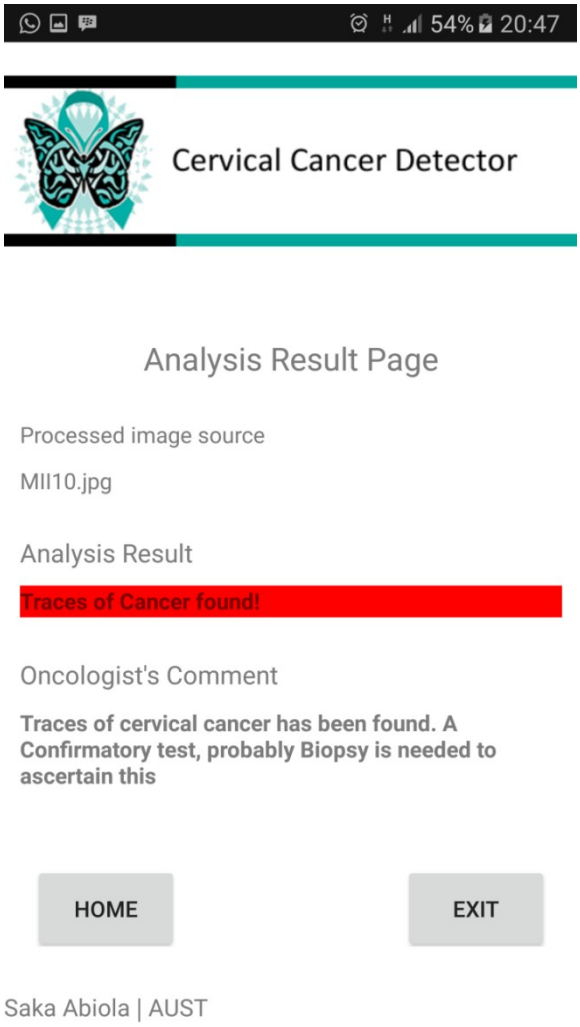

Result page – Traces of cancer found

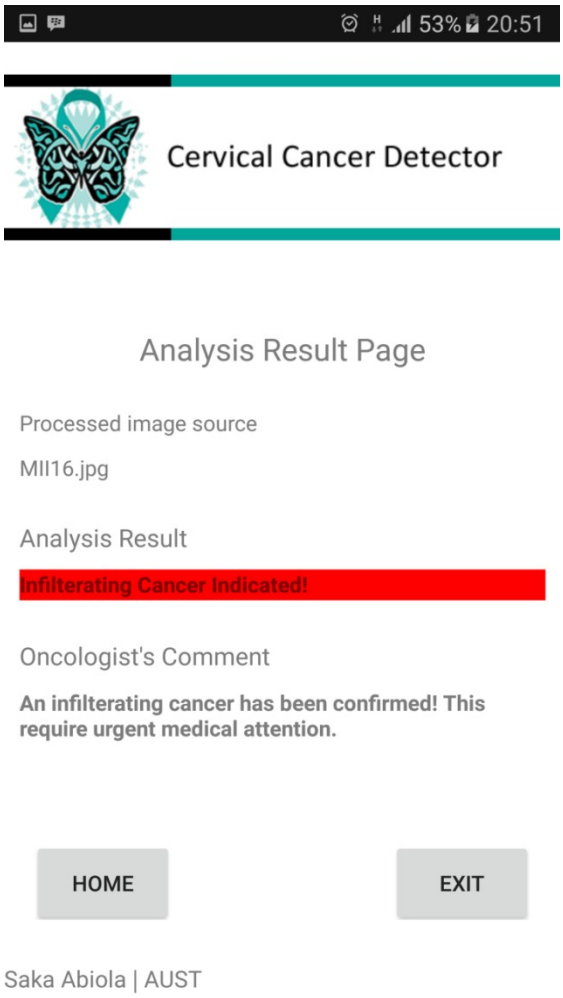

Result page - High grade cancer found

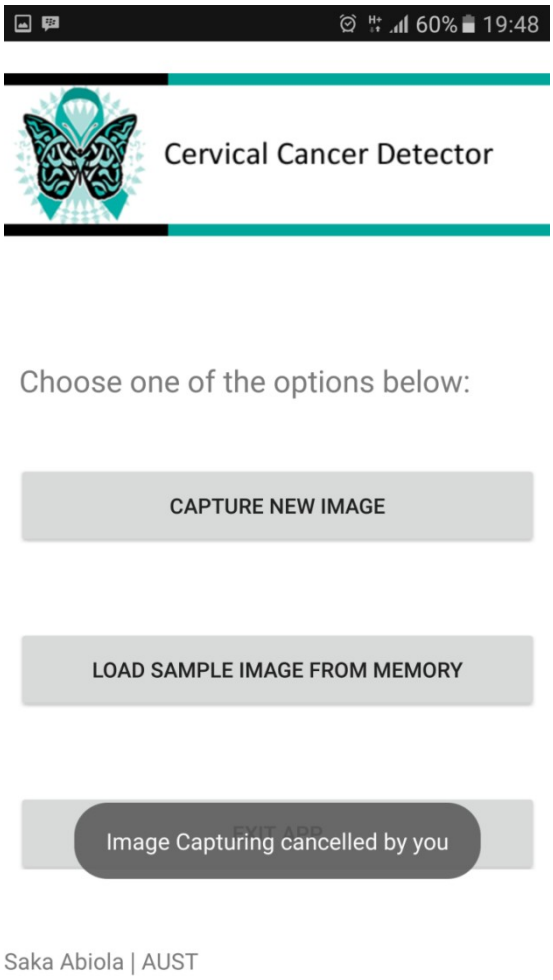

When the camera interface was interrupted

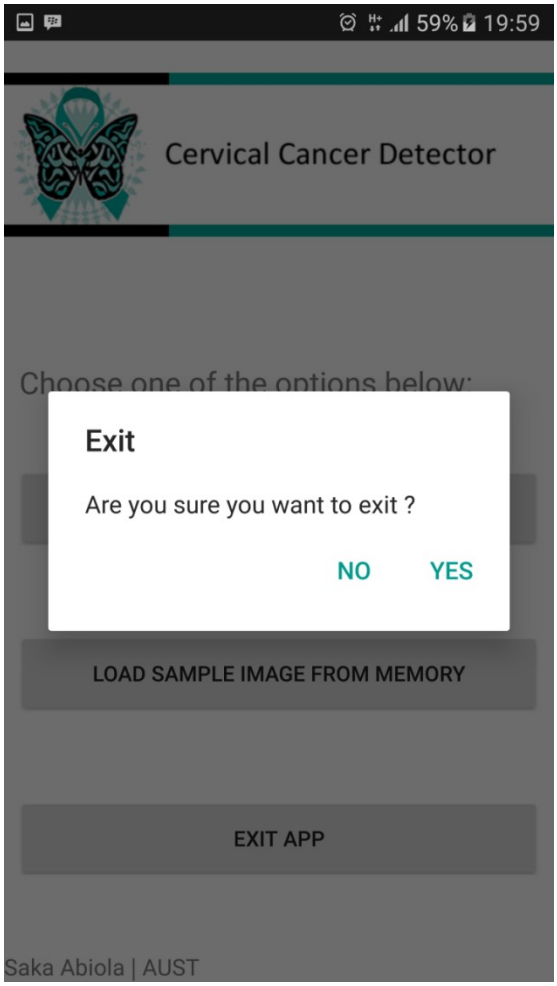

Exit App Button – For closing the app

Sample Code

HomeScreen Activity (Homescreen.java)

```
package com.aust.monsur.cervicalcancer;

import android.app.Activity;
import android.app.AlertDialog;
import android.content.DialogInterface;
import android.content.Intent;
import android.content.pm.PackageManager;
import android.net.Uri;
import android.os.Bundle;
import android.os.Environment;
import android.os.Process;
import android.provider.MediaStore;
import android.util.Log;
import android.view.View;
import android.widget.Button;
import android.widget.Toast;

import java.io.File;
import java.text.SimpleDateFormat;
import java.util.Date;
import java.util.Locale;

/**
 * Created by monsur on 3/10/16.
 */
public class Homescreen extends Activity{
    Button btnFromCamera;
    Button btnFromMemory;
    Button btnExit;
    Uri fileUri,gFileUri;
    private final static String IMAGE_DIRECTORY = "cancerImages";
    private final static  int REQUEST_CODE = 100;
    private final static  int REQUEST_PATH=200;
    String fileName;


    protected void onCreate(Bundle savedInstanceState){
        super.onCreate(savedInstanceState);
        requestWindowFeature(1);
        setContentView(R.layout.activity_homescreen);

        btnFromCamera = (Button) findViewById(R.id.btnSnapNewImage);
        btnFromMemory = (Button) findViewById(R.id.btnLoadFromMemory);
```

```
        btnExit = (Button) findViewById(R.id.btnExit);

        btnFromCamera.setOnClickListener(new View.OnClickListener() {
            @Override
            public void onClick(View v) {
                if(isCameraPresent()){
                    captureImage();
                }
            }
        });

        btnFromMemory.setOnClickListener(new View.OnClickListener() {
            @Override
            public void onClick(View v) {
                getFilePath();
            }
        });

        btnExit.setOnClickListener(new View.OnClickListener() {
            @Override
            public void onClick(View v) {
                showExitDialog();
            }
        });

    }

    protected void showExitDialog(){
        AlertDialog.Builder ab = new AlertDialog.Builder(Homescreen.this);
                                ab.setTitle("Exit").setMessage("Are you sure you want to
exit ?").setPositiveButton("Yes", new DialogInterface.OnClickListener(){
            public void onClick(DialogInterface diag, int num){
                moveTaskToBack(true);
                Process.killProcess(Process.myPid());
                System.exit(1);
            }
        }).setNegativeButton("No", new DialogInterface.OnClickListener(){
                    public void onClick(DialogInterface paramAnonymousDialogInterface, int
paramAnonymousInt)
            {
                paramAnonymousDialogInterface.cancel();
            }
        });
        ab.create().show();
    }

    private boolean isCameraPresent(){
        if(getApplicationContext().getPackageManager().hasSystemFeature(PackageManager.F
EATURE_CAMERA)) {
            return true;
```

```
    }else{
        return false;
    }
}

private void captureImage(){
    Intent in = new Intent(MediaStore.ACTION_IMAGE_CAPTURE);
    fileUri = getFileUri();
    in.putExtra(MediaStore.EXTRA_OUTPUT, fileUri);
    startActivityForResult(in,REQUEST_CODE);
}

@Override
protected void onActivityResult(int requestCode, int resultCode, Intent in){
    if(requestCode==REQUEST_CODE){
        if(resultCode==RESULT_OK){
            Bundle b = new Bundle();
            String path =  fileUri.getPath();

            b.putString("filee", path);
            b.putString("fileName","From Camera");
            b.putBoolean("from",true);
            Log.e("Camera Captured :", path);
            Intent intent = new Intent(Homescreen.this, Image_display.class);
           // intent.putExtra("filee", path);
            intent.putExtras(b);
            startActivity(intent);
        }else if(resultCode==RESULT_CANCELED){
                        Toast.makeText(getBaseContext(), "Image Capturing cancelled by
you",Toast.LENGTH_LONG).show();
        }
    }else if(requestCode==REQUEST_PATH){
        if(resultCode==RESULT_OK){
            //the path to the file
            String path = in.getStringExtra("getFilePath");
            String fileName = in.getStringExtra("getFileName");
            Bundle b = new Bundle();
            //b.putParcelable("filee",fileName );
            b.putString("filee",path+"/"+fileName);
            b.putBoolean("from", false);
            b.putString("fileName",fileName);
            Log.e("Image Copied :", path+"/"+fileName);
            Intent intent = new Intent(Homescreen.this, Image_display.class);
            intent.putExtras(b);
            startActivity(intent);
        }else{
                                Toast.makeText(getApplicationContext(),"Error  copying
image",Toast.LENGTH_LONG).show();
        }
    }
```

```
    }

    //ensuring that the captured image is not lost after the activity return to the calling one
    protected void onSaveInstanceState(Bundle out){
        super.onSaveInstanceState(out);
        //gFileUri = fileUri;
        out.putParcelable("file_uri", fileUri);
    }

    protected void onRestoreInstanceState(Bundle in){
        super.onRestoreInstanceState(in);
       fileUri =  in.getParcelable("file_uri");
    }

    private Uri getFileUri(){
        return Uri.fromFile(getMediaFile());
    }

    private  File getMediaFile(){
        //SD card location
                                                    File        sd_storage        =        new
File(Environment.getExternalStoragePublicDirectory(Environment.DIRECTORY_PICTURE
S),IMAGE_DIRECTORY);
        //create folder is not exist
        File mediaFile;
        if(!sd_storage.exists()) {
            if (!sd_storage.mkdir()) {
                        Toast.makeText(getApplicationContext(), "Error creating directory " +
IMAGE_DIRECTORY, Toast.LENGTH_LONG).show();
            }
        }
                            String   ts   =   new   SimpleDateFormat("yyyyMMdd_HHmmss",
Locale.getDefault()).format(new Date());
            mediaFile = new File(sd_storage.getPath()+File.separator+"IMG_"+ts+".jpg");
            //return mediaFile;
        return  mediaFile;
    }

    private void getFilePath(){
        Intent intent = new Intent(Homescreen.this,FileChooser.class);
        startActivityForResult(intent,REQUEST_PATH);
   }}
```

Image Display Activity

```
package com.aust.monsur.cervicalcancer;

import android.app.Activity;
import android.app.ProgressDialog;
import android.content.Intent;
import android.graphics.Bitmap;
```

```
import android.graphics.BitmapFactory;
import android.net.Uri;
import android.os.AsyncTask;
import android.os.Bundle;
import android.os.Environment;
import android.os.Looper;
import android.util.Log;
import android.view.View;
import android.widget.Button;
import android.widget.ImageView;
import android.widget.Toast;

import java.io.ByteArrayOutputStream;
import java.io.File;
import java.io.FileOutputStream;
import java.io.IOException;
import java.util.Random;


/**
 * Created by monsur on 3/10/16.
 */
public class Image_display extends Activity{

    ImageView imgDisplay,testDisplay;
    Button btnAnalyse;
    Bitmap bit,grayImage,edgesImg;
    ProgressDialog progress;
    String fileName;
    Utility util = new Utility();
    CannyEdge canny = new CannyEdge();
    Segmentation segment = new Segmentation();
    Boolean flag;
    static final String IMAGE_FOLDER = "cancer_images";



    protected void onCreate(Bundle savedInstanceState){
        super.onCreate(savedInstanceState);
        requestWindowFeature(1);
        setContentView(R.layout.activity_display);

        imgDisplay = (ImageView) findViewById(R.id.displayImage);
        testDisplay = (ImageView) findViewById(R.id.displayTestImage);
        btnAnalyse = (Button) findViewById(R.id.btnAnaly);

        Intent in = getIntent();
        String path = in.getExtras().getString("filee");
        flag = in.getExtras().getBoolean("from");
```

```
    fileName = in.getExtras().getString("fileName");
    display_Image(path,flag);

    btnAnalyse.setOnClickListener(new View.OnClickListener() {
        @Override
        public void onClick(View v) {
            Bitmap[] bitm = new Bitmap[1];
            bitm[0] = bit;
          new  Analyse().execute(bit);
        }
    });
}

private void displayImage(Uri fileUri){
    try {
        imgDisplay.setVisibility(View.VISIBLE);

        BitmapFactory.Options op = new BitmapFactory.Options();
        op.inSampleSize = 16;
        final Bitmap bit = BitmapFactory.decodeFile(fileUri.getPath(),op);
        imgDisplay.setImageBitmap(bit);
    }catch(NullPointerException e){
        e.printStackTrace();
    }
}

private void display_Image(String path, Boolean fromCamera){
    try {
        imgDisplay.setVisibility(View.VISIBLE);

        BitmapFactory.Options op = new BitmapFactory.Options();
        if(fromCamera) {
            //reduce to image to avoid running out of memory error for large images
            op.inSampleSize = 64;
        }
        bit = BitmapFactory.decodeFile(path,op);

        imgDisplay.setImageBitmap(bit);
    }catch(NullPointerException e){
        e.printStackTrace();
    }
}

private void display_bitmap(Bitmap img){
    imgDisplay.setImageBitmap(img);
}

private void saveImage(Bitmap finalBitmap) {
```

```
File sd_storage = new File(Environment.getExternalStoragePublicDirectory(Environment.DIRECTORY_PICTURES),IMAGE_FOLDER);
    if (!sd_storage.exists()) {

        if (!sd_storage.mkdirs()) {
            Log.d(IMAGE_FOLDER, "Oops! Failed create " + IMAGE_FOLDER + " directory");
        }
    }
    Random generator = new Random();
    int n = 10000;
    n = generator.nextInt(n);
    String fname = "Image-"+ n +".jpg";
    File file = new File (sd_storage, fname);
    if (file.exists ()) file.delete ();
    try {
        FileOutputStream out = new FileOutputStream(file);
        finalBitmap.compress(Bitmap.CompressFormat.JPEG, 100, out);
        out.flush();
        out.close();
    } catch (Exception e) {
        e.printStackTrace();
    }
  }

  private class Analyse extends AsyncTask<Bitmap, String, double[]>{

    protected void onPreExecute(){
      super.onPreExecute();
      progress = new ProgressDialog(Image_display.this);
      progress.setTitle("Analysis");
      progress.setMessage("Performing the Image Analysis\nplease wait..");
      progress.setCancelable(false);
      progress.show();

    }

    protected double[] doInBackground(Bitmap...args){
      try {
        MedianFilter mf = new MedianFilter(args[0]);
        Bitmap res = mf.applyFilter();
        segment.setSourceImg(res); //pass the image
        segment.performSegmentation();
        Bitmap roi = segment.getSegmentedImg();
        Bitmap finalRoiRgb = segment.separate(roi);
        grayImage = util.convertToGray(finalRoiRgb);
        canny.setSourceImg(grayImage);
        canny.process();
        edgesImg = canny.getEdgesImg();
```

```
            double mean = util.meanValue(edgesImg);
            double sd = util.standardDeviation(edgesImg);
            double[] result= new double[2];
            result[0] = mean;
            result[1] = sd;
            return result;
        } catch(Exception e) {
            e.printStackTrace();
        }
        return null;
    }

    protected void onPostExecute(double[] result){
        super.onPostExecute(result);
        progress.dismiss();
        if(result==null){
                Toast.makeText(Image_display.this.getApplicationContext(),"Image analysis
error\nPlease try again later", Toast.LENGTH_LONG).show();
        }else{
            Intent in = new Intent(Image_display.this,Result_display.class);
            in.putExtra("results", result);
            in.putExtra("fileName",fileName);
            startActivity(in);
        }
    }
  }
}
```

Median Filter Activity

```
package com.aust.monsur.cervicalcancer;

/**
 * Created by monsur on 5/10/16.
 */
import android.graphics.Bitmap;
import android.graphics.Color;
import android.util.Log;

import java.util.ArrayList;
import java.util.Collections;


public class MedianFilter extends ImageFilter {
```

```
public MedianFilter(Bitmap image) {
   super(image);
}

public MedianFilter(Bitmap image, int size) {
   super(image, size);
}

@Override
public Bitmap applyFilter() {

   int width = bitmap.getWidth();
   int height = bitmap.getHeight();
   int offset = maskSize/2;

   // Retrieve pixels of bitmap for efficiency
   int[] pixels = BitmapUtils.getPixels(bitmap);

   // Iterate over all pixels of image determine new values
   for (int y = 0; y < height; y++) {
      for (int x = 0; x < width; x++) {

         // If filtering has been asked to cancel, stop filtering
         if (cancelFiltering) {
            return null;
         }

         ArrayList<Integer> reds = new ArrayList<Integer>(offset);
         ArrayList<Integer> greens = new ArrayList<Integer>(offset);
         ArrayList<Integer> blues = new ArrayList<Integer>(offset);
         ArrayList<Integer> alphas = new ArrayList<Integer>(offset);

         // Retrieve mask pixels and calculate median value for new pixel
         // This is done primitively for efficiency
         for (int row = y-offset; row <= y+offset; row++) {
            for (int col = x-offset; col <= x+offset; col++) {
               if (row >= 0 && col >= 0 && row < height && col < width) {

                  int color = pixels[row*width+col];

                  reds.add(Color.red(color));
                  greens.add(Color.green(color));
                  blues.add(Color.blue(color));
                  alphas.add(Color.alpha(color));
               }
            }
         }

         int red = getMedian(reds);
```

```
            int green = getMedian(greens);
            int blue = getMedian(blues);
            int alpha = getMedian(alphas);

            pixels[y*width+x] = Color.argb(alpha,red,green,blue);
        }
    }
    Log.e("Bitmaps from Specle ", pixels+"");
    return Bitmap.createBitmap(pixels,width,height,bitmap.getConfig());
  }

  /**
   * Returns the median value of the passed value list
   */
  private int getMedian(ArrayList<Integer> values) {
    Collections.sort(values);
    int size = values.size();

    if (size % 2 != 0) {
        return values.get(size/2);
    } else {
        return (values.get(size/2) + values.get(size/2 - 1))/2;
    }
  }
}
```

Segmentation Class

```
package com.aust.monsur.cervicalcancer;

import android.content.Context;
import android.graphics.Bitmap;
import android.graphics.Color;
import android.util.Log;
import android.widget.Toast;

/**
 * Created by monsur on 5/13/16.
 */
public class Segmentation {
  Context context;

  private final int L_THRESHOLD = 95;
  private final int U_THRESHOLD = 98;
  private int height;
  private int width;
  private int picSize;
  private int[] data;
```

```
    private int[] magnitude;
    private Bitmap sourceImg;
    private Bitmap newImage;
    private Bitmap segmentedImg;
    private boolean isOriginUpperLeft = true;

    public void setSourceImg (Bitmap sourceImg_) {
        sourceImg = sourceImg_.copy(Bitmap.Config.ARGB_8888, true);
                newImage  =  Bitmap.createBitmap(sourceImg.getWidth(),  sourceImg.getHeight(),
Bitmap.Config.ARGB_8888);
       // Toast.makeText(this.context," Just Show", Toast.LENGTH_LONG ).show();
    }

    public void performSegmentation(){
        height = sourceImg.getHeight();
        width = sourceImg.getWidth();
        for(int i = 0; i < width; i++) {
            for(int j = 0; j < height; j++) {
                int value = sourceImg.getPixel(i, j);
                double lum = lum(value);
                Log.e("Lum value ", lum+"");
                if(lum <=L_THRESHOLD){ //|| getRGB(value)>200
                    sourceImg.setPixel(i,j,Color.BLACK);
                }
            }
        }
        segmentedImg = sourceImg;
    }

    public Bitmap separate(Bitmap roi){
        for(int i=0 ; i< roi.getWidth(); i++){
            for(int j = 0; j<roi.getHeight(); j++){
                int rgb = getRGB(roi.getPixel(i,j));
                Log.e("ROI RGB ", rgb+"");
                if(rgb>120)
                    roi.setPixel(i,j,Color.BLACK);
            }
        }
        return roi;
    }

    public  double lum(int pixValue) {
        int r = Color.red(pixValue);
        int g = Color.green(pixValue);
        int b = Color.blue(pixValue);
        return .299*r + .587*g + .114*b;//.299*r + .587*g + .114*b;
    }

    public  int getRGB(int pixValue) {
        int r = Color.red(pixValue);
```

```
        int g = Color.green(pixValue);
        int b = Color.blue(pixValue);
        return (r + g + b)/3;
    }

    public Bitmap getSegmentedImg () {
        return segmentedImg;
    }

    public Bitmap getNewImage () {
        return newImage;
    }

}
```

Result page

```
package com.aust.monsur.cervicalcancer;

import android.app.Activity;
import android.app.AlertDialog;
import android.content.DialogInterface;
import android.content.Intent;
import android.graphics.Color;
import android.graphics.Typeface;
import android.os.Bundle;
import android.os.Process;
import android.util.Log;
import android.view.View;
import android.widget.Button;
import android.widget.TextView;
import android.widget.Toast;


/**
 * Created by monsur on 3/10/16.
 */
public class Result_display extends Activity {

   // String fileName;
    double[] result;
    double mean, sd;
    TextView imageName, analysisResult, comment;
    Button btnHome,btnExitApp;


    protected void onCreate(Bundle savedInstanceState){
        super.onCreate(savedInstanceState);
        setContentView(R.layout.activity_result);
```

```
        imageName = (TextView)findViewById(R.id.imageName);
        analysisResult = (TextView)findViewById(R.id.result);
        comment = (TextView)findViewById(R.id.comment);
        btnHome = (Button) findViewById(R.id.btnHome);
        btnExitApp = (Button)findViewById(R.id.btnExitApp);

        comment.setTypeface(null, Typeface.BOLD);
        analysisResult.setTypeface(null,Typeface.BOLD);
        btnHome.setOnClickListener(new View.OnClickListener() {
            @Override
            public void onClick(View v) {
                startActivity(new Intent(getApplicationContext(),Homescreen.class));
            }
        });

        btnExitApp.setOnClickListener(new View.OnClickListener() {
            @Override
            public void onClick(View v) {
                AlertDialog.Builder ab = new AlertDialog.Builder(Result_display.this);
                                ab.setTitle("Exit").setMessage("Are you sure you want to
exit ?").setPositiveButton("Yes", new DialogInterface.OnClickListener(){
                    public void onClick(DialogInterface diag, int num){
                        moveTaskToBack(true);
                        Process.killProcess(Process.myPid());
                        System.exit(1);
                    }
                }).setNegativeButton("No", new DialogInterface.OnClickListener(){
                     public void onClick(DialogInterface paramAnonymousDialogInterface, int
paramAnonymousInt)
                    {
                        paramAnonymousDialogInterface.cancel();
                    }
                });
                ab.create().show();
            }
        });

        Intent in = getIntent();
        imageName.setText(in.getStringExtra("fileName"));

        result = in.getDoubleArrayExtra("results");

        process(result);


    }

    public void process(double[] results){
        mean = results[0];
```

```
        sd = results[1];
        String no_cancer = "This image sample shows no traces of cancer. Please repeat this test in the next three month";
        String cancer = "Traces of cervical cancer has been found. A Confirmatory test, probably Biopsy is needed to ascertain this";
        String inconclusive = "An infilterating cancer has been confirmed! This require urgent medical attention. ";

      if(mean<10.0){
         analysisResult.setText("No traces of cancer found!");
         analysisResult.setBackgroundColor(Color.GREEN); //set to green

         comment.setText(no_cancer);
      }else if(mean>10.0 && mean<20.0){
         analysisResult.setText("Traces of Cancer found!");
         analysisResult.setBackgroundColor(Color.RED); //set to red

         comment.setText(cancer);

      }else{
         analysisResult.setText("Infilterating Cancer Indicated!");
         analysisResult.setBackgroundColor(Color.RED); //set to orange

         comment.setText(inconclusive);
      }
   }
}
```

Interface Design

Homescreen.xml

```
<ScrollView
   xmlns:android="http://schemas.android.com/apk/res/android"
   android:fillViewport="true"
   android:layout_width="fill_parent"
   android:layout_height="fill_parent">

        <RelativeLayout  android:background="#ffffff"  android:layout_width="fill_parent" android:layout_height="wrap_content">
                <LinearLayout  android:id="@id/header"  android:paddingBottom="5dp" android:layout_width="fill_parent" android:layout_height="wrap_content">
            <ImageView android:id="@+id/logoImg" android:layout_width="wrap_content" android:layout_height="fill_parent"  android:src="@drawable/cervical_logo" android:contentDescription="@string/txtLogo" />
      </LinearLayout>
```

```
                <LinearLayout   android:orientation="vertical"   android:id="@id/footer"
android:layout_width="fill_parent"                    android:layout_height="wrap_content"
android:layout_marginTop="50dp" android:layout_alignParentBottom="true">
                        <TextView   android:textSize="15sp"   android:id="@id/txtFooter"
android:layout_width="fill_parent"                    android:layout_height="wrap_content"
android:text="@string/txtFooter" />
    </LinearLayout>

        <LinearLayout android:orientation="vertical" android:id="@id/registrationForm"
android:padding="10dp"                                  android:layout_width="fill_parent"
android:layout_height="wrap_content"                     android:layout_marginTop="20dp"
android:layout_marginBottom="50dp" android:layout_below="@id/header">
        <TextView
           android:textSize="20sp"
           android:layout_width="fill_parent"
           android:layout_height="wrap_content"
           android:layout_marginTop="25dp"
           android:layout_marginBottom="25dp"
           android:text="@string/lblWelcomeHome"
           android:id="@+id/txtEmail" />


        <Button
           android:id="@+id/btnSnapNewImage"
           android:layout_width="fill_parent"
           android:layout_height="wrap_content"
           android:layout_marginTop="20dp"
           android:layout_marginBottom="40dp"
           android:text="@string/lblSnapNewImage"
           android:contentDescription="@string/lblConfirm" />

        <Button
        android:id="@+id/btnLoadFromMemory"
        android:layout_width="fill_parent"
        android:layout_height="wrap_content"
        android:layout_marginTop="20dp"
        android:layout_marginBottom="40dp"
        android:text="@string/lblLoadFromMemory"
        android:contentDescription="@string/lblConfirm" />


        <Button
           android:id="@+id/btnExit"
           android:layout_width="fill_parent"
           android:layout_height="wrap_content"
           android:layout_marginTop="20dp"
           android:text="@string/exit"
           android:contentDescription="@string/lblConfirm" />
```

```
<!--        <ImageView    android:id="@+id/code_resend"
android:layout_width="fill_parent"                    android:layout_height="25dp"
android:layout_marginBottom="40dp"                    android:src="@drawable/resend_code"
android:contentDescription="@string/lblConfirm" />
    --> </LinearLayout>
  </RelativeLayout>
</ScrollView>
```

Result page

```
<ScrollView
  xmlns:android="http://schemas.android.com/apk/res/android"
  android:fillViewport="true"
  android:layout_width="fill_parent"
  android:layout_height="fill_parent">

      <RelativeLayout  android:background="#ffffff"  android:layout_width="fill_parent"
android:layout_height="wrap_content">
                <LinearLayout  android:id="@id/header"  android:paddingBottom="5dp"
android:layout_width="fill_parent" android:layout_height="wrap_content">
          <ImageView android:id="@+id/logoImg" android:layout_width="wrap_content"
android:layout_height="fill_parent"                    android:src="@drawable/cervical_logo"
android:contentDescription="@string/txtLogo" />
    </LinearLayout>

                <LinearLayout  android:orientation="vertical"  android:id="@id/footer"
android:layout_width="fill_parent"                    android:layout_height="wrap_content"
android:layout_marginTop="50dp" android:layout_alignParentBottom="true">
                        <TextView  android:textSize="15sp"  android:id="@id/txtFooter"
android:layout_width="fill_parent"                    android:layout_height="wrap_content"
android:text="@string/txtFooter" />
    </LinearLayout>

    <LinearLayout
      android:orientation="vertical"
      android:id="@id/registrationForm"
      android:padding="10dp"
      android:layout_width="fill_parent"
      android:layout_height="wrap_content"
      android:layout_marginTop="20dp"
      android:layout_marginBottom="20dp"
      android:layout_below="@id/header"
      android:weightSum="1">
```

```
    <TextView
        android:layout_width="match_parent"
        android:layout_height="wrap_content"
        android:text="Analysis Result Page"
        android:gravity="center"
        android:textSize="20sp"/>
    <TextView
        android:layout_width="fill_parent"
        android:layout_height="wrap_content"
        android:layout_marginTop="25dp"
        android:layout_marginBottom="10dp"
        android:text="Processed image source"
        android:layout_weight="0.17" />

    <TextView
        android:layout_width="match_parent"
        android:layout_height="wrap_content"
        android:id="@+id/imageName"/>

    <TextView
        android:layout_width="fill_parent"
        android:layout_height="wrap_content"
        android:layout_marginTop="25dp"
        android:layout_marginBottom="10dp"
        android:text="Analysis Result"
        android:textSize="16sp"
        android:layout_weight="0.17" />

    <TextView
    android:layout_width="match_parent"
    android:layout_height="20dp"
    android:id="@+id/result"/>

    <TextView

        android:layout_width="fill_parent"
        android:layout_height="wrap_content"
        android:layout_marginTop="25dp"
        android:layout_marginBottom="10dp"
        android:text="Oncologist's Comment"
        android:textSize="16sp"
        android:layout_weight="0.17" />

    <TextView
        android:layout_width="match_parent"
        android:layout_height="wrap_content"
        android:id="@+id/comment"/>

</LinearLayout>
<LinearLayout
```

```
        android:layout_width="match_parent"
        android:layout_height="wrap_content"
        android:layout_marginTop="500dp">
        <RelativeLayout
            android:layout_width="match_parent"
            android:layout_height="wrap_content"
            android:padding="20dp"
            >

            <Button
            android:id="@+id/btnHome"
            android:layout_width="wrap_content"
            android:layout_height="wrap_content"
            android:layout_alignParentLeft="true"
            android:text="Home"/>

            <Button
                android:id="@+id/btnExitApp"
                android:layout_width="wrap_content"
                android:layout_height="wrap_content"
                android:layout_alignParentRight="true"
                android:text="Exit"/>


        </RelativeLayout>
    </LinearLayout>

  </RelativeLayout>
</ScrollView>
```